

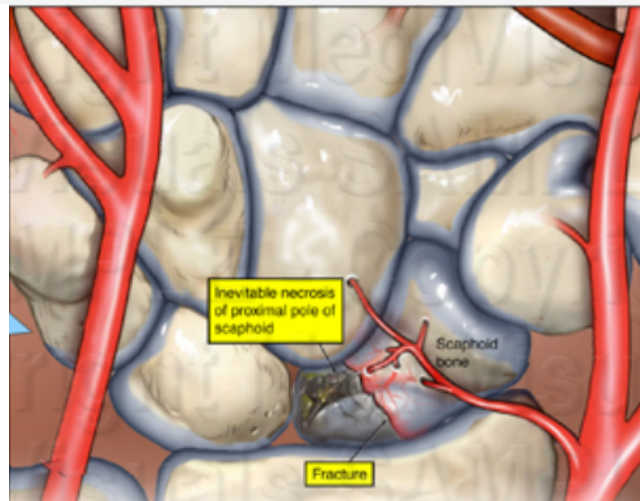
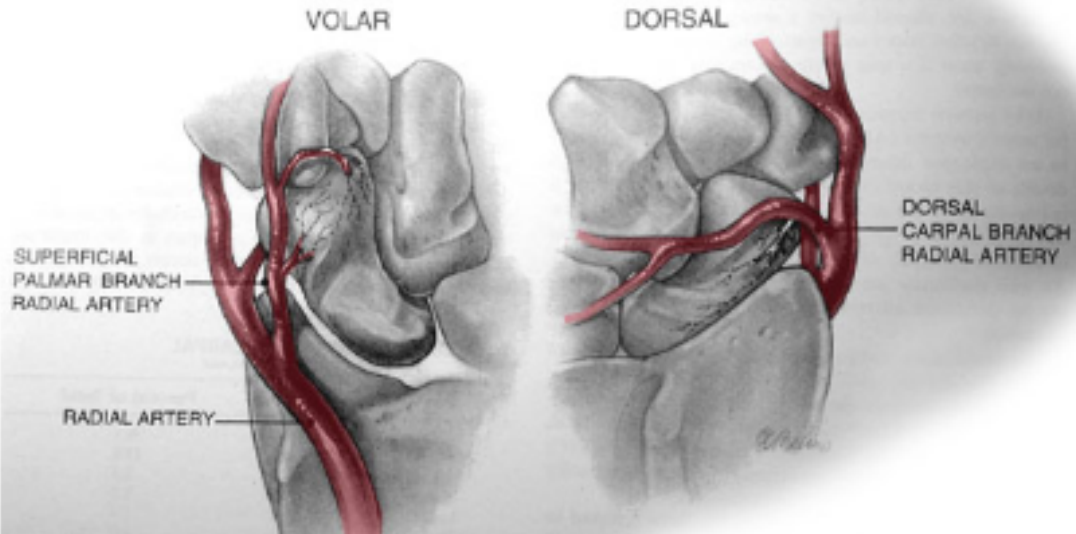
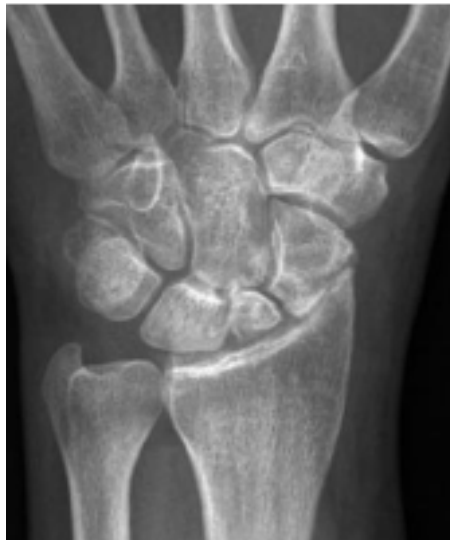# **SCAPHOID EXCISION AND FOUR-CORNER FUSION IN THE TREATMENT OF SCAPHOID NONUNION ADVANCED COLLAPSE**

**LE NGOC TUAN.MD**

**LE GIA ANH THY.MD**

# SNAC

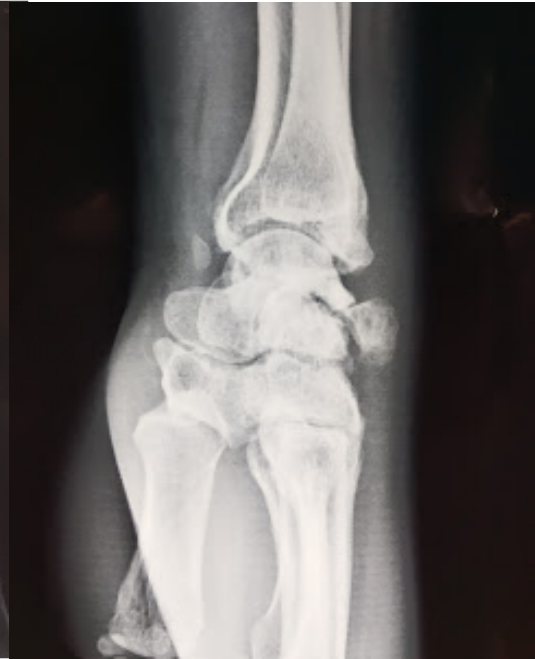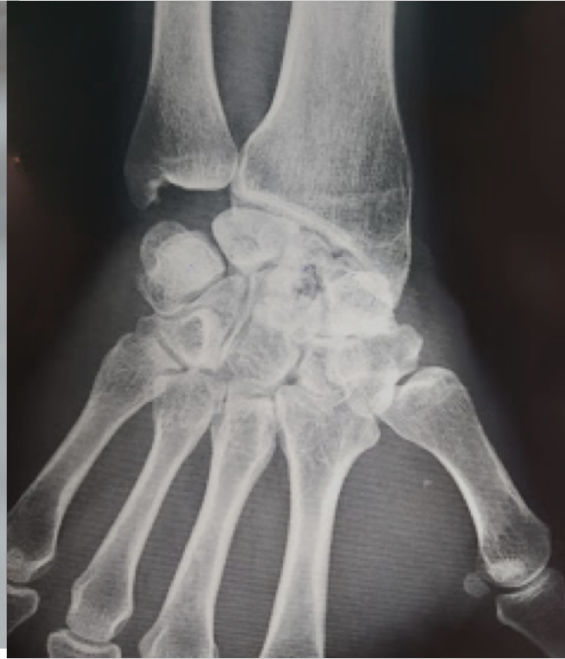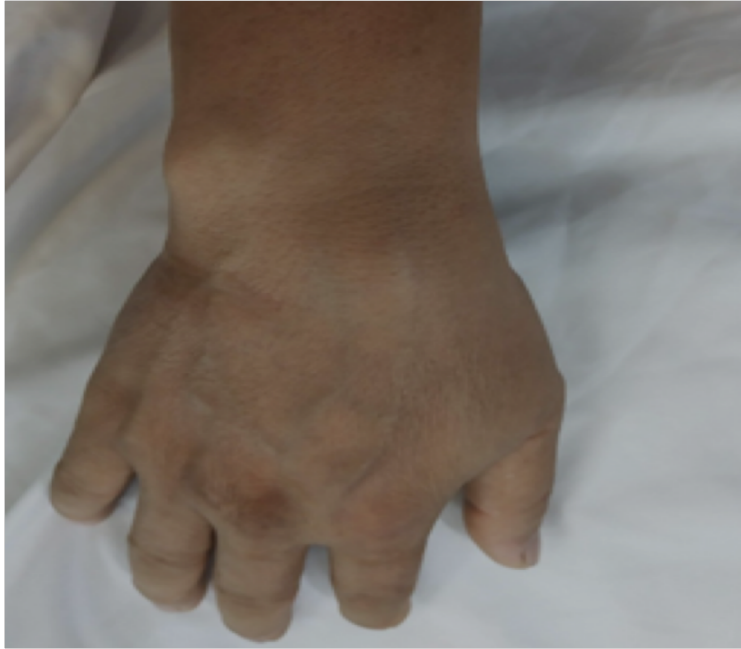(Scaphoid nonunion advanced collapse)



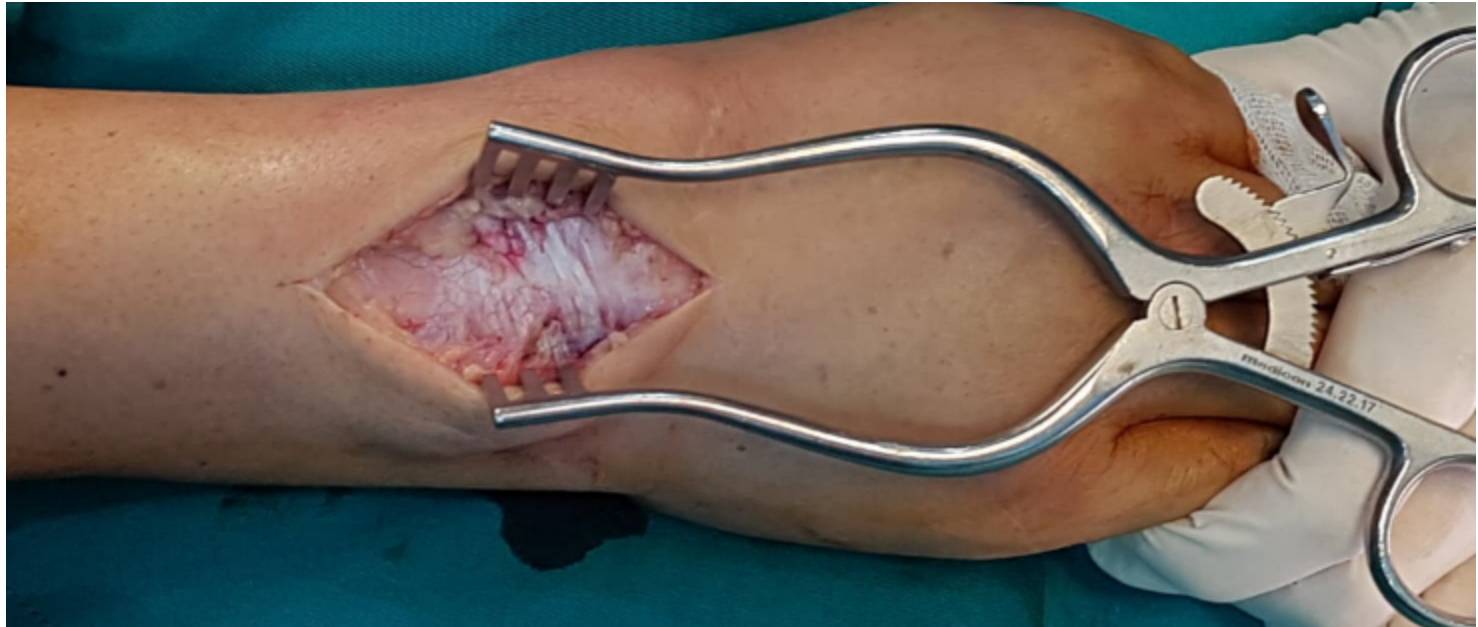# CASE 1

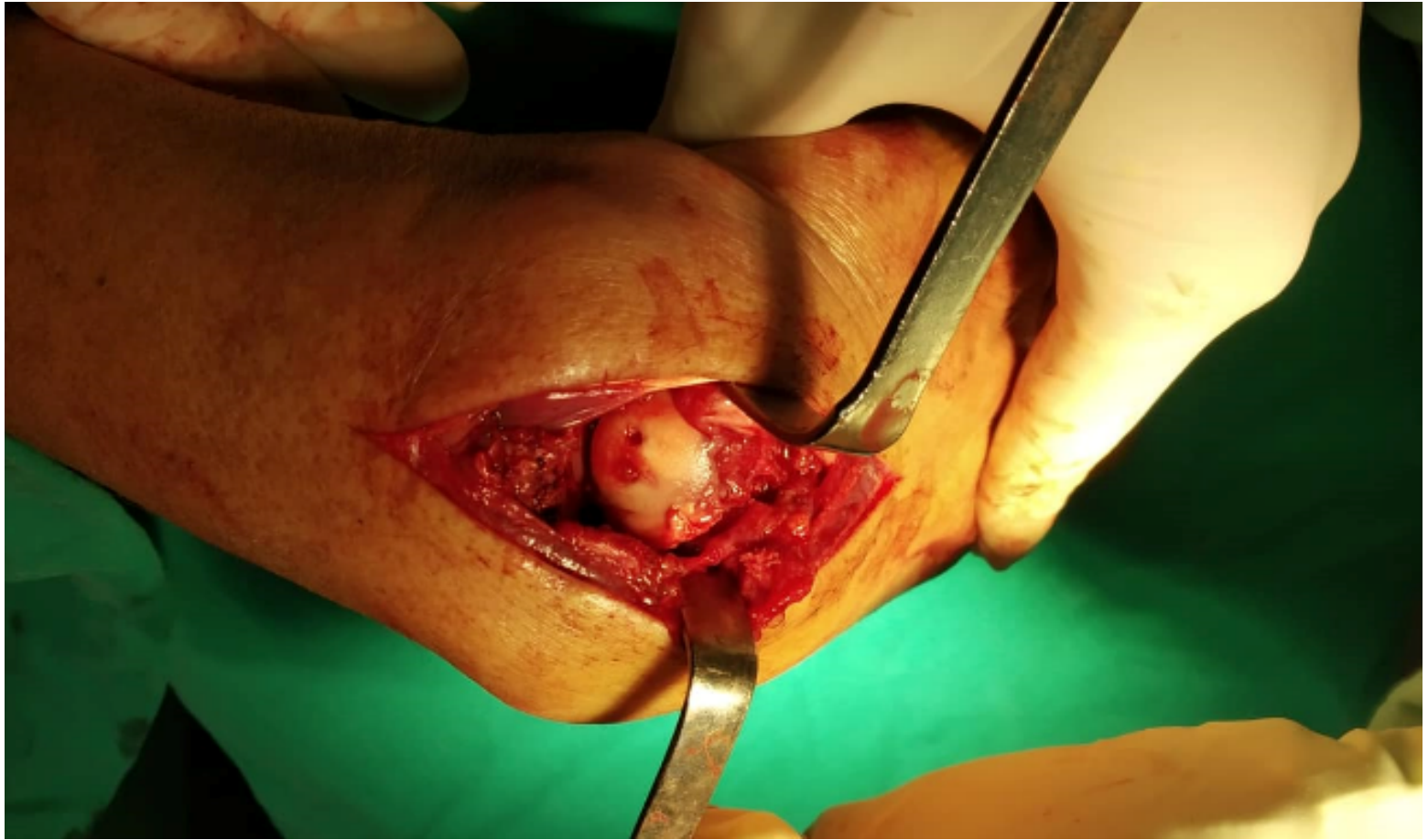
- Tran Thanh T, 1976, M
- 1998:Đồng Nai Hospital: diagnosed: R **wrist sprain**
- First treatments: splint
- 2018 (20 years): HTO
- SNAC: stage II

# PRE OP

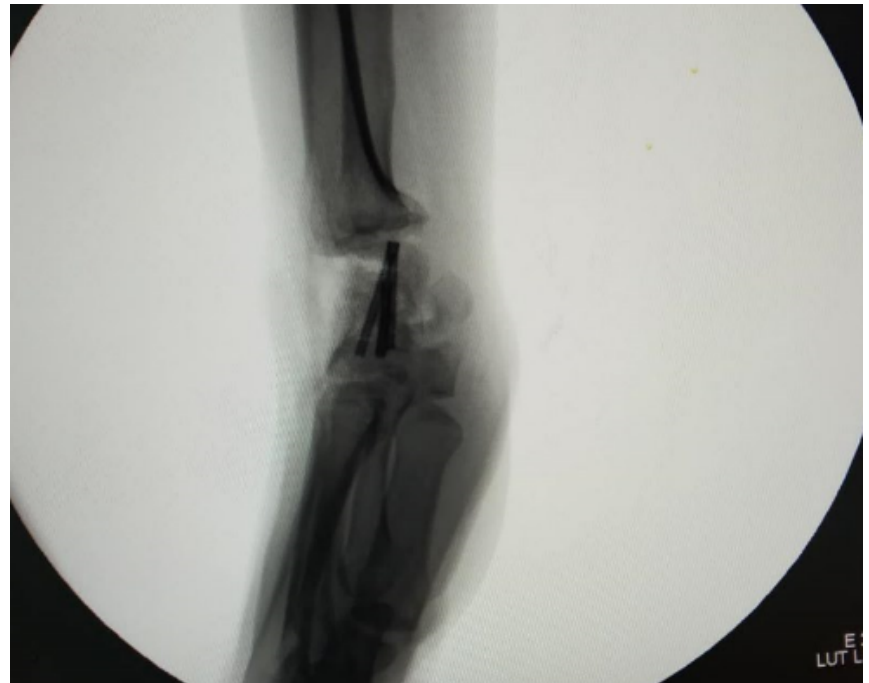
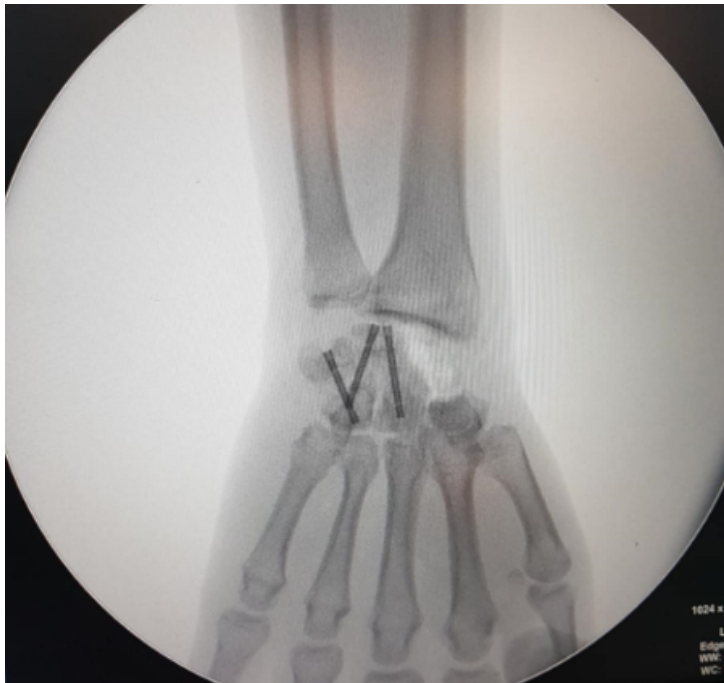
OP

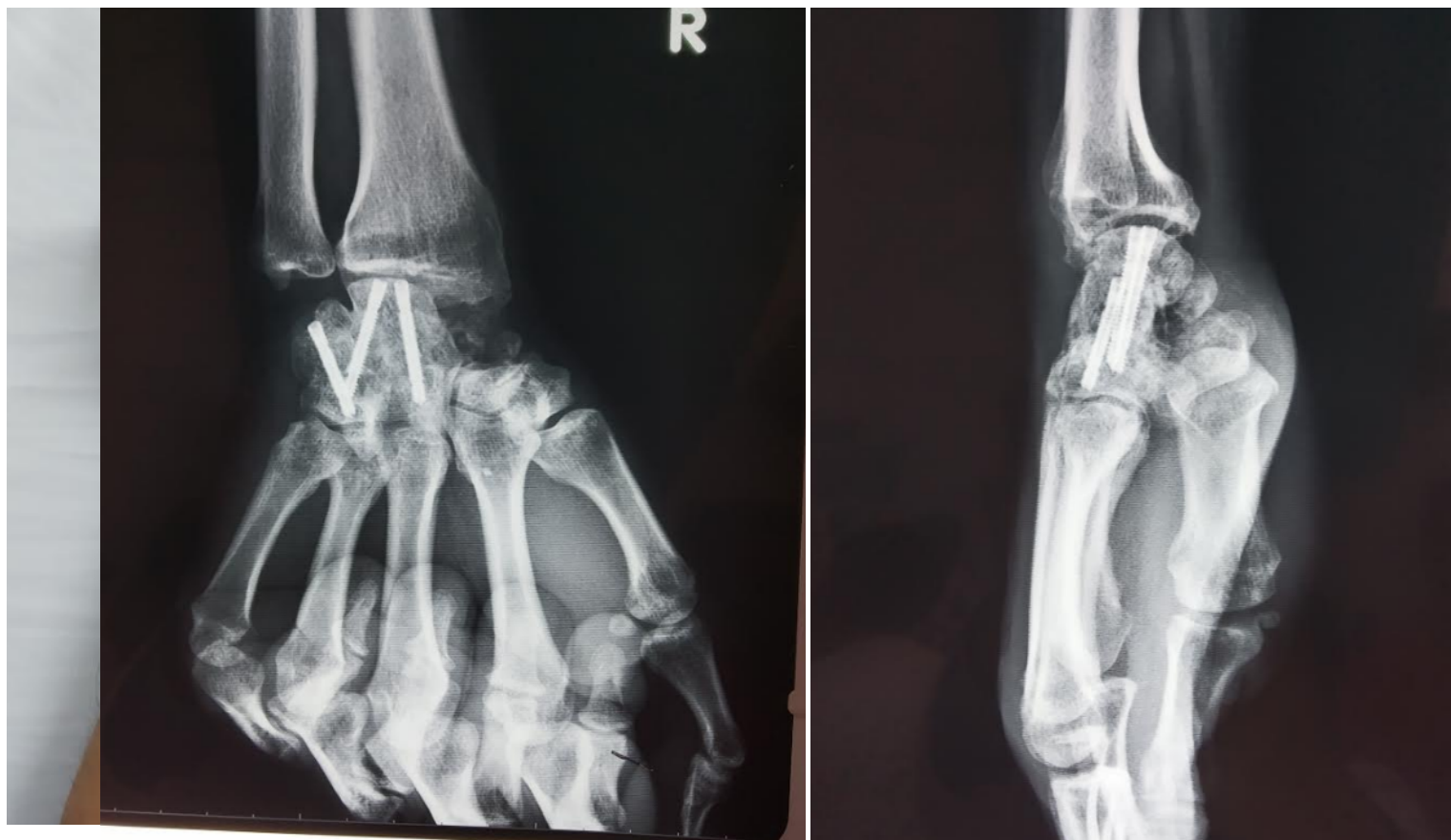




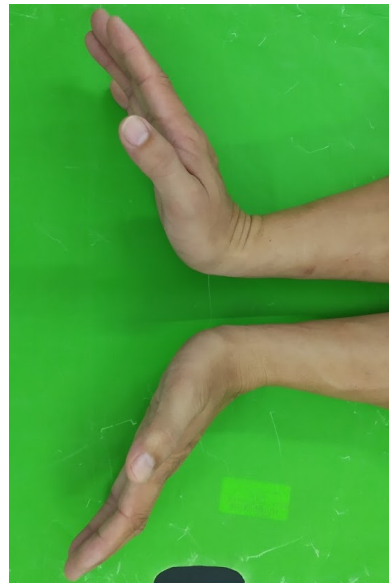

# POST OP



# POST OP 10 MONTHS



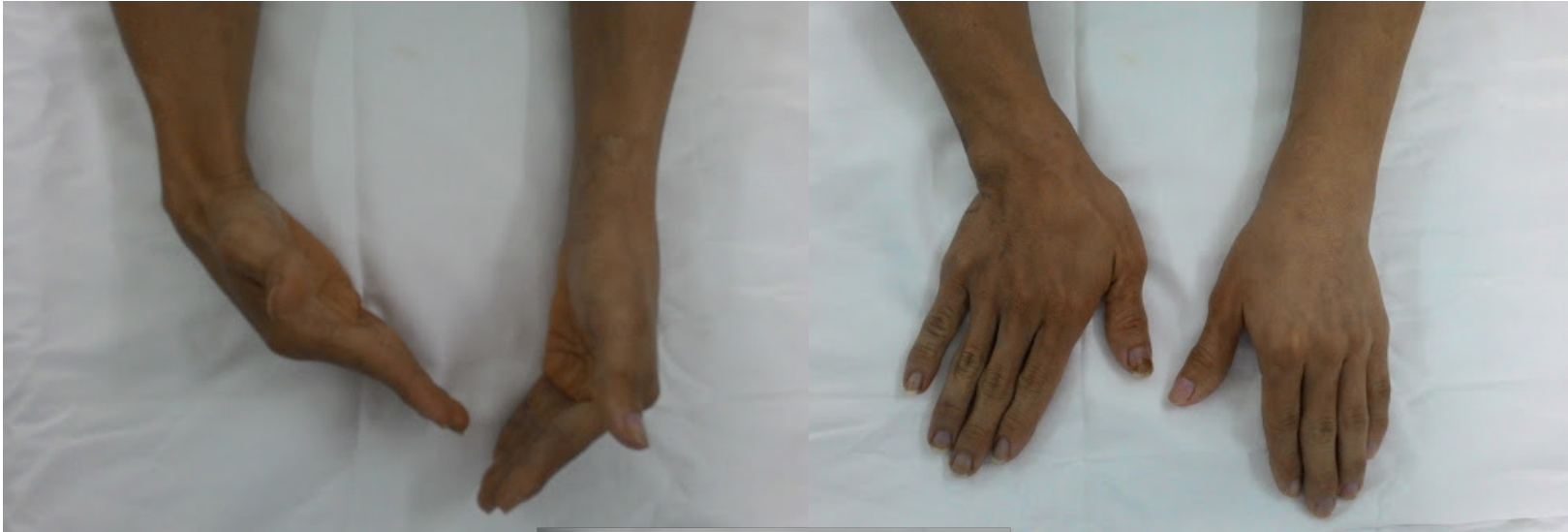# POST OP 10 MONTHS



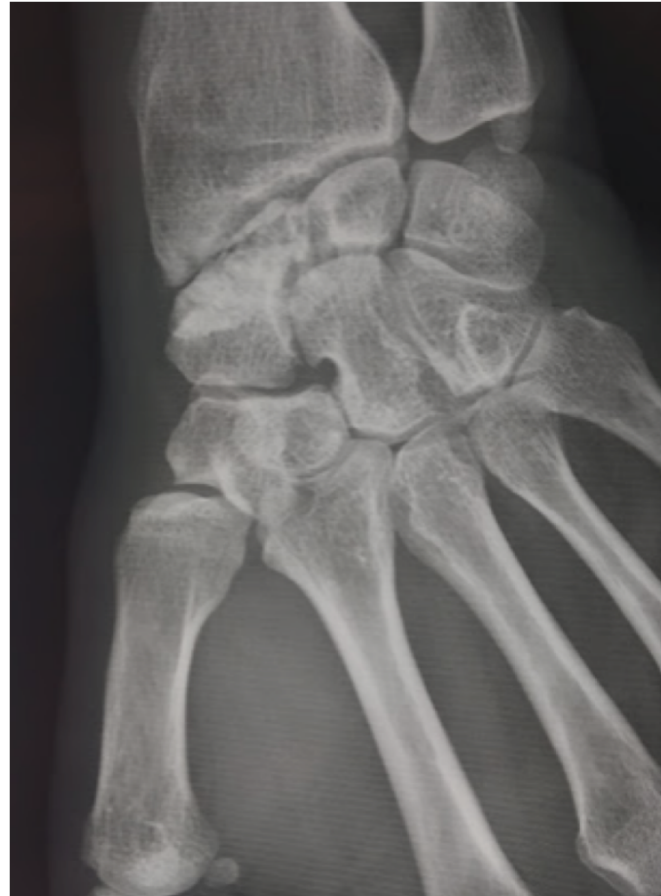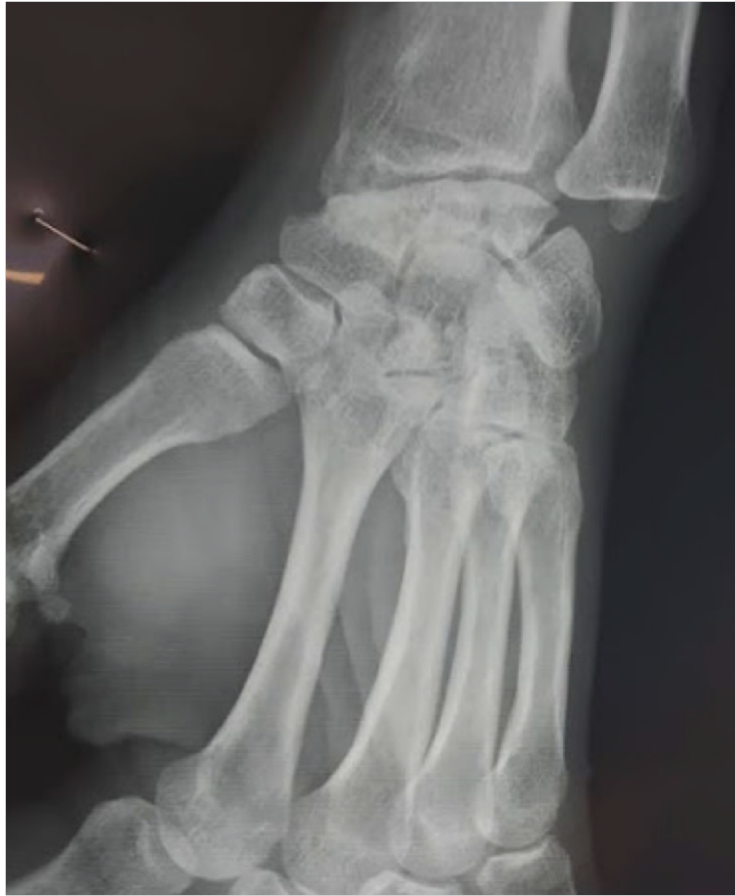## CASE 2

- Nguyen Van P, 1973, M
- Fall from Height in 2008:Tien Giang Hospital:  
diagnosed: L wrist sprain
- First treatments: splint
- 2018 (10 years): HTO
- SNAC: stage II

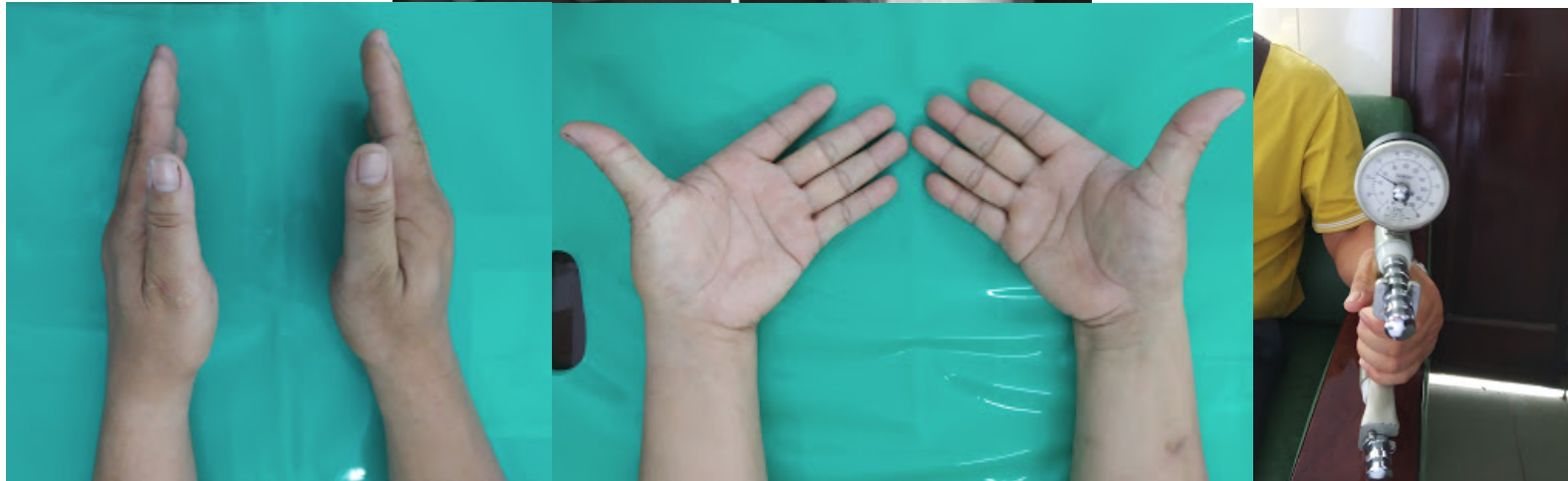
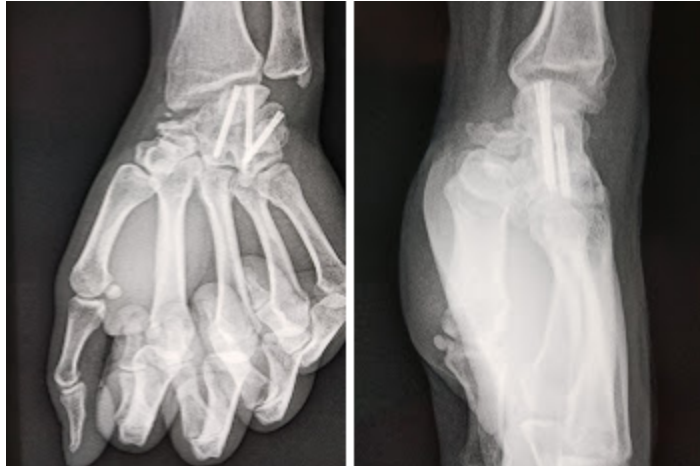# PRE OP



# X RAY



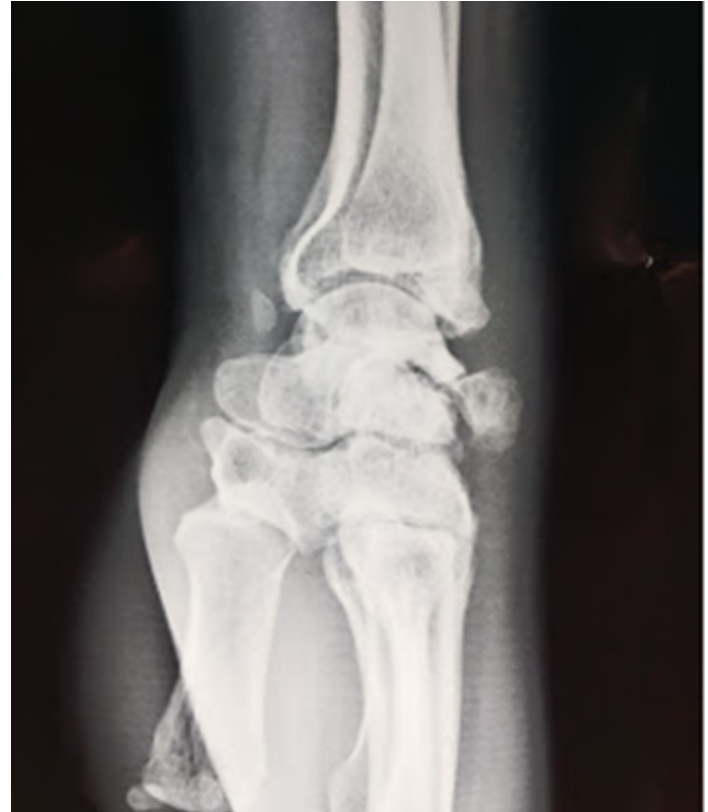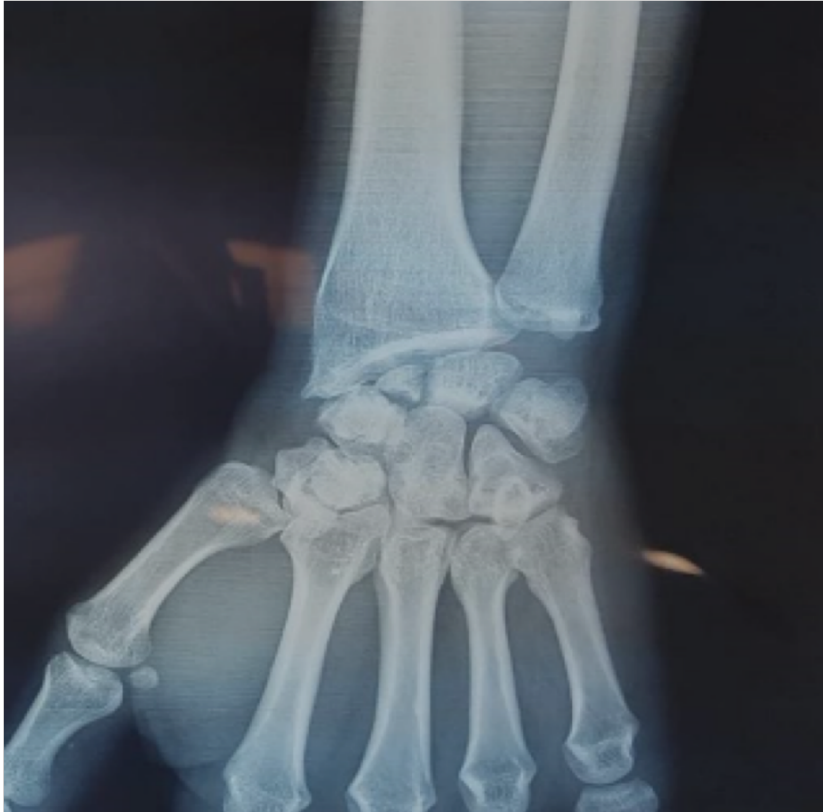# POST OP 6 MONTHS



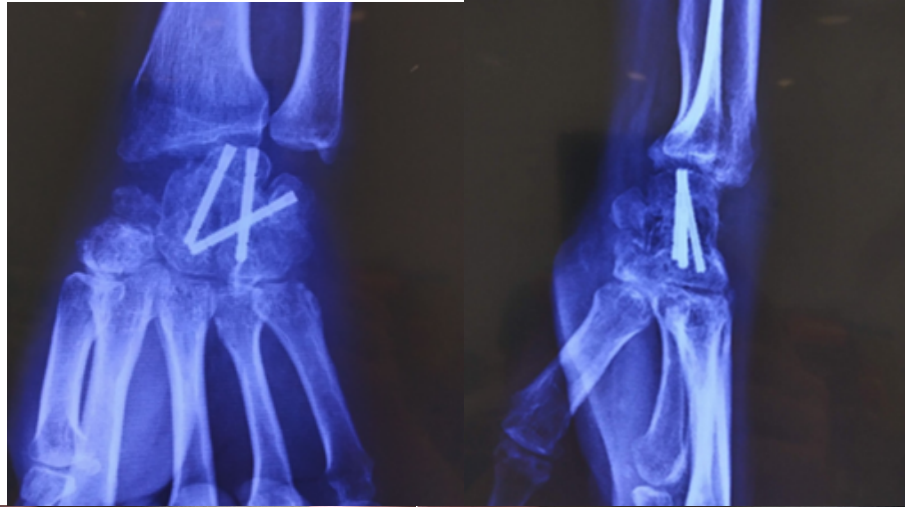
## CASE 3

- Đàng Van N, 1979, M
- Sport injury
- 2000:Lâm Đồng Hospital: diagnosed: L **wrist sprain**
- First treatments: splint
- 2018 (18 years): HTO
- SNAC: stage II

# X RAY



# POST OP 5 MONTHS

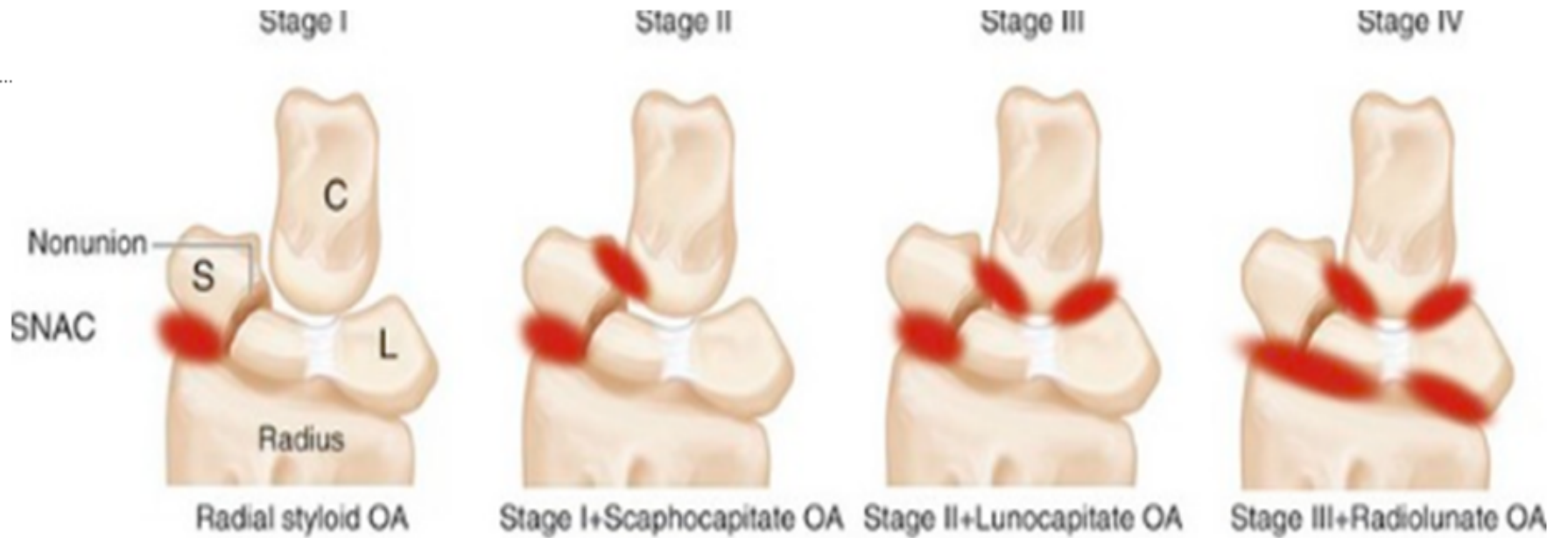


# RESULT

## **Mayo and Cooney Wrist Score**

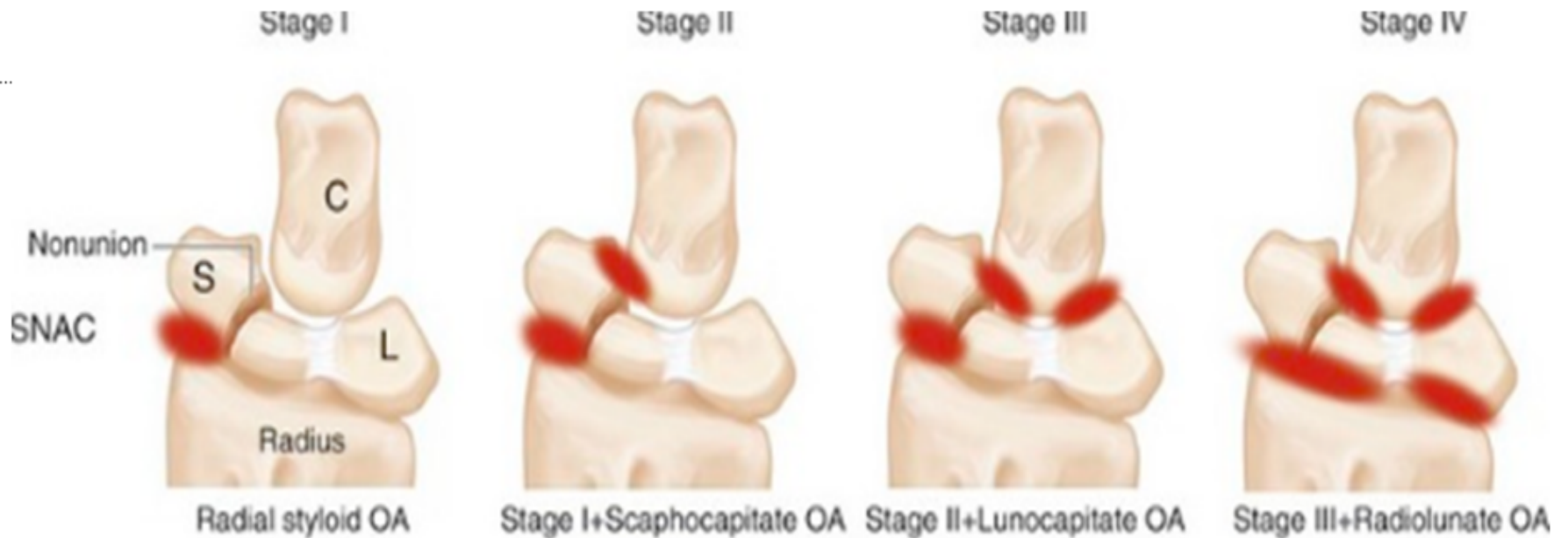
- Pain Intensity
- Functional status
- Range of Motion
- Grip strength

# CLASSIFICATION

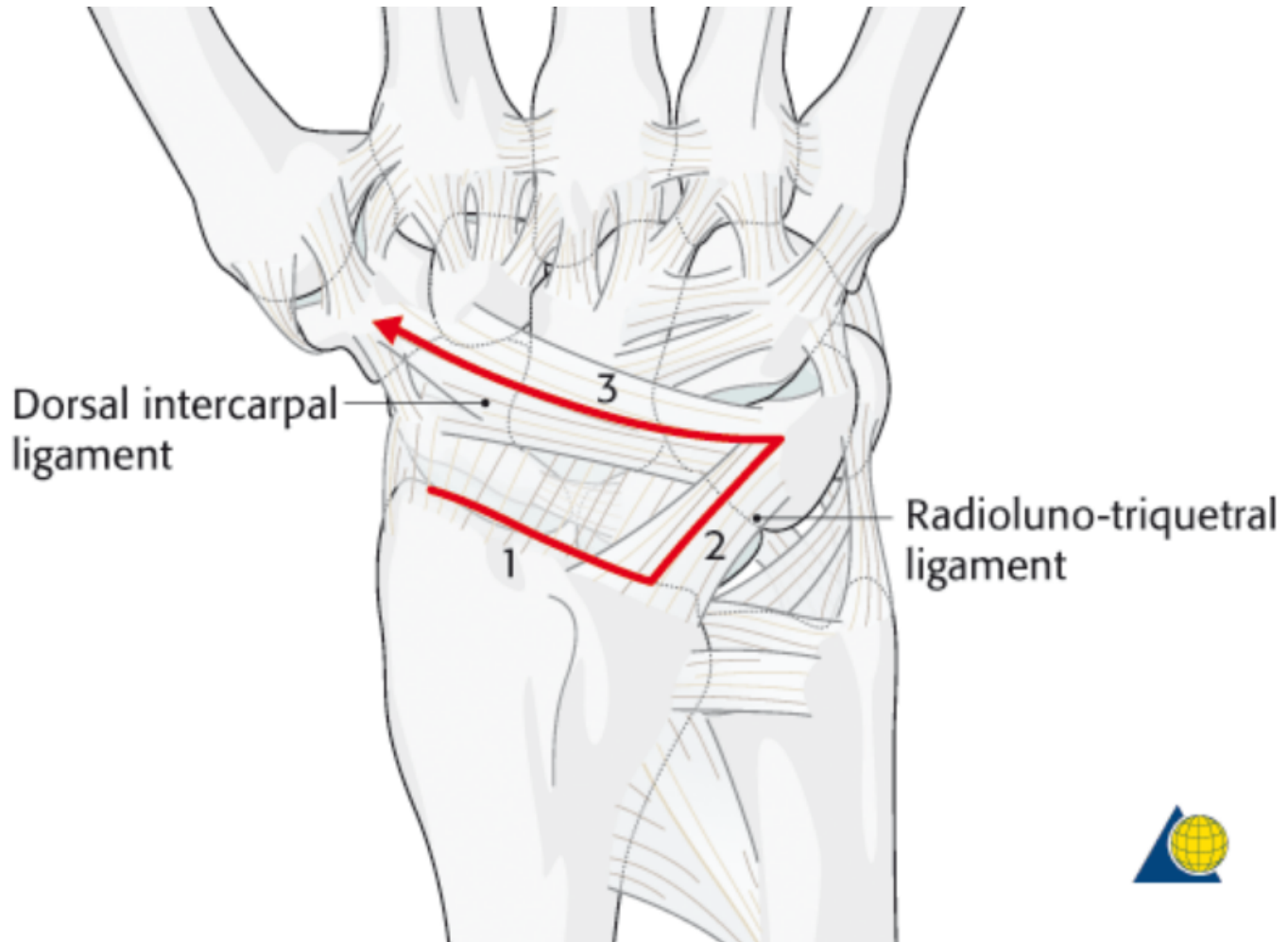


# INDICATIONS

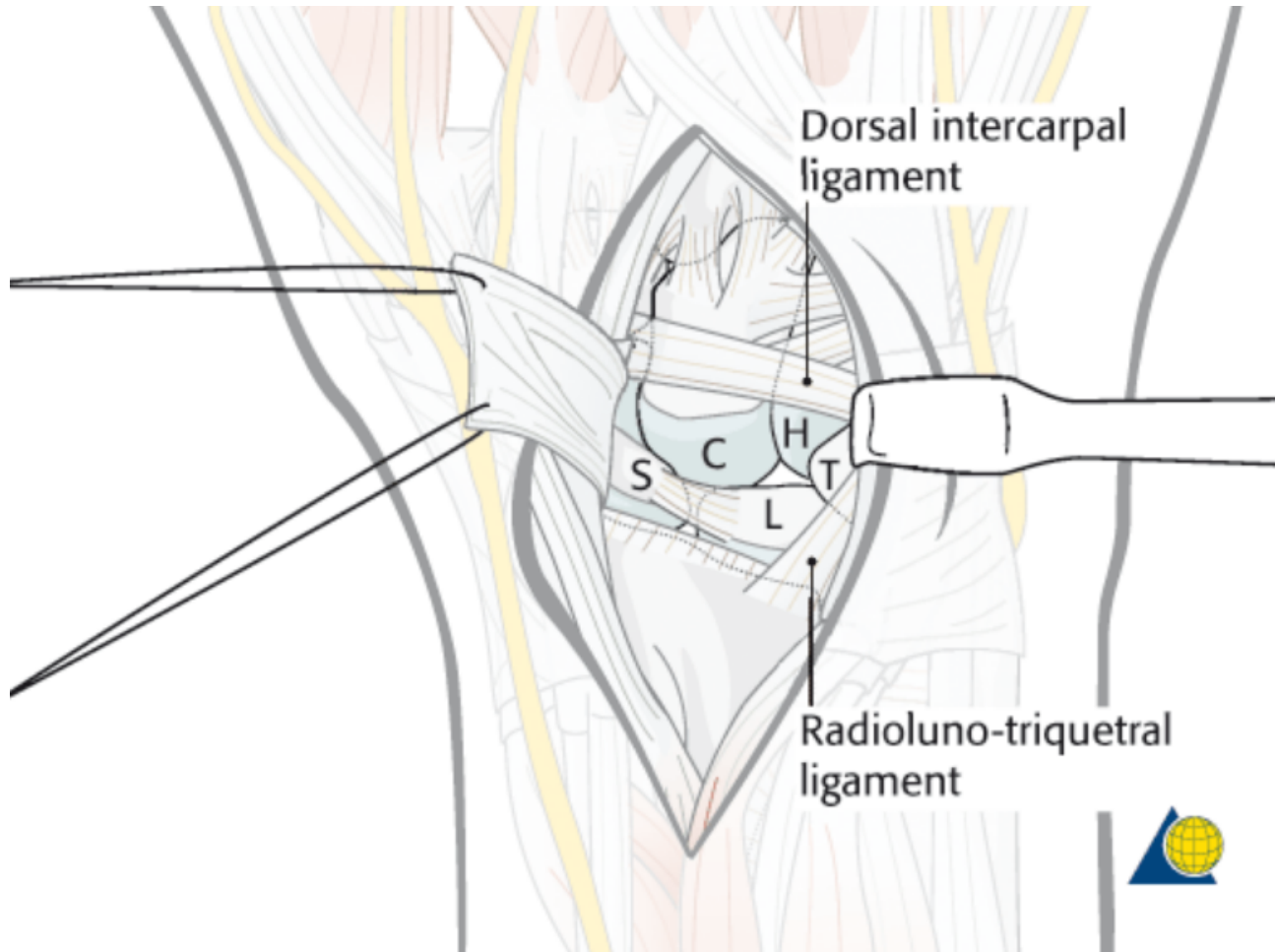
SNAC: stage II, stage III



# APPROACH

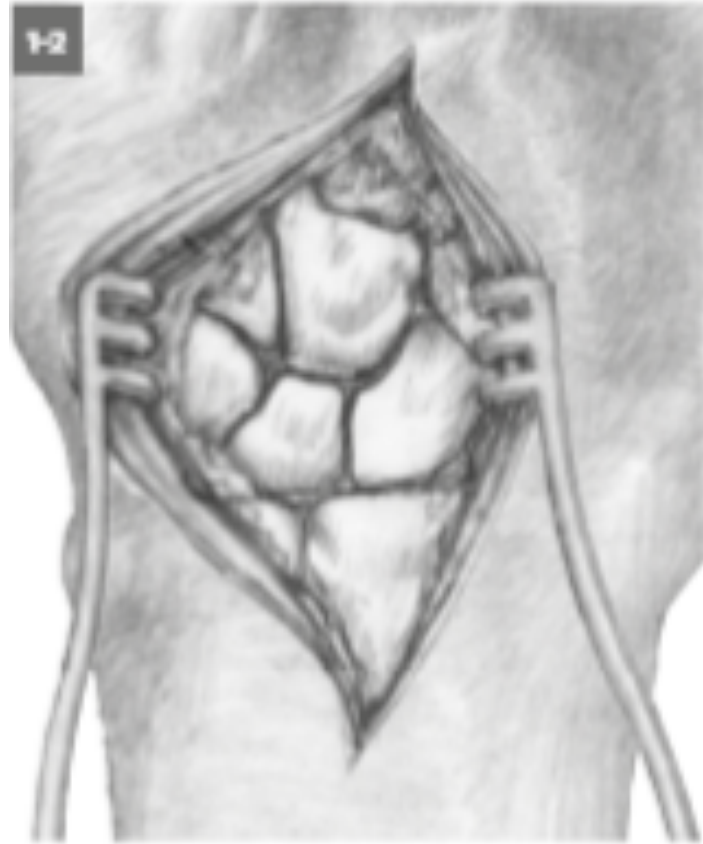
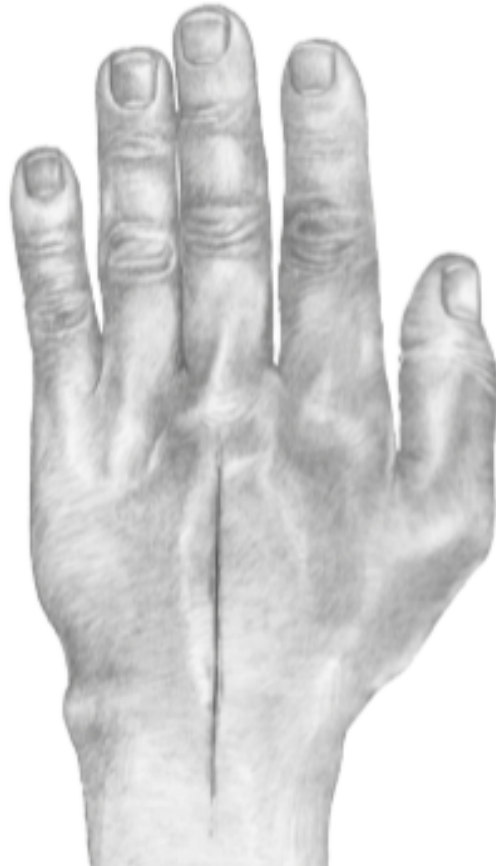
# APPROACH



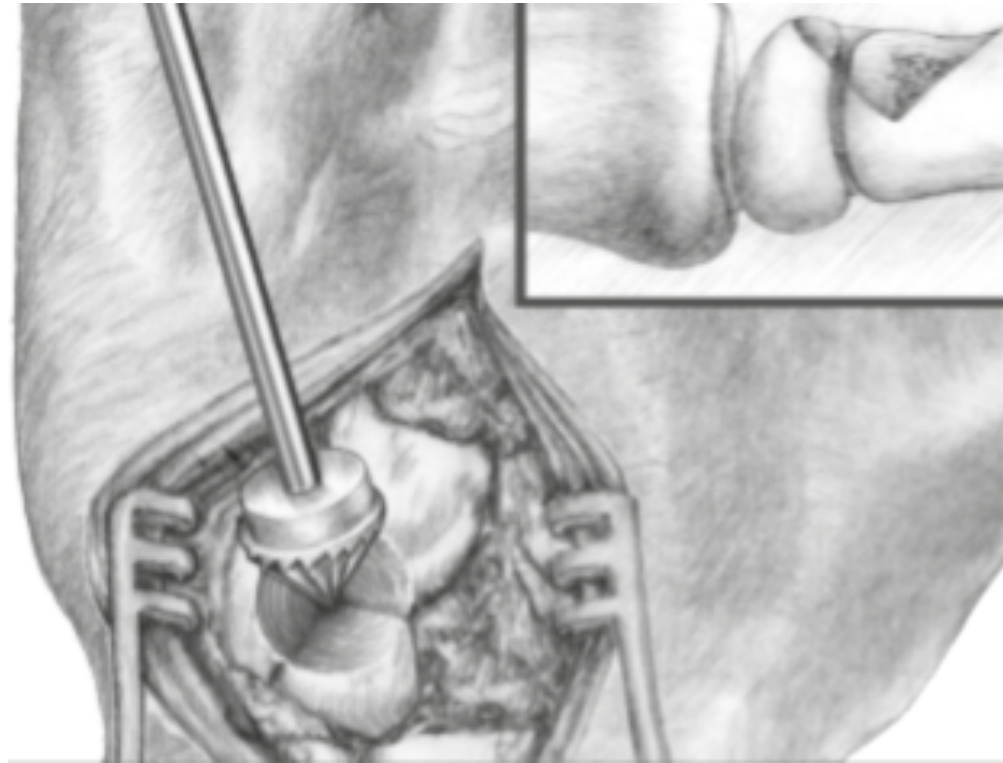
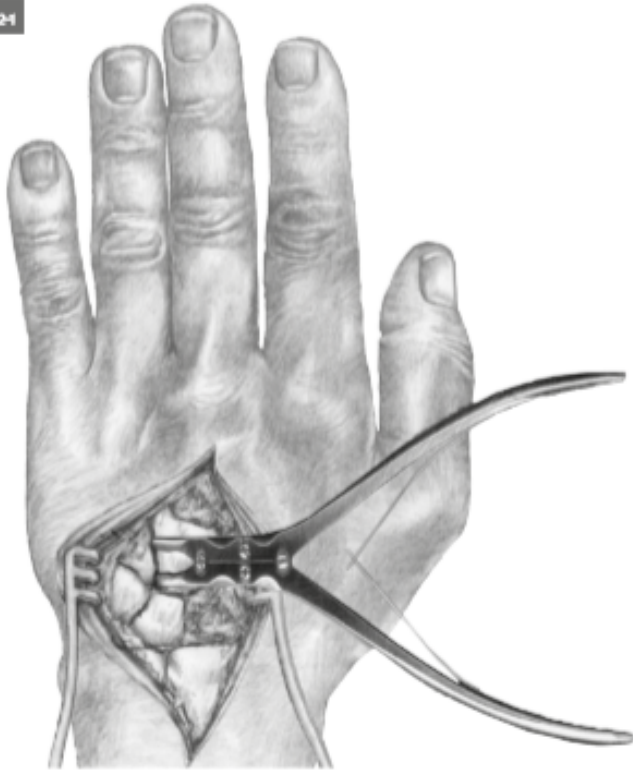
# TECHNIQUES

1

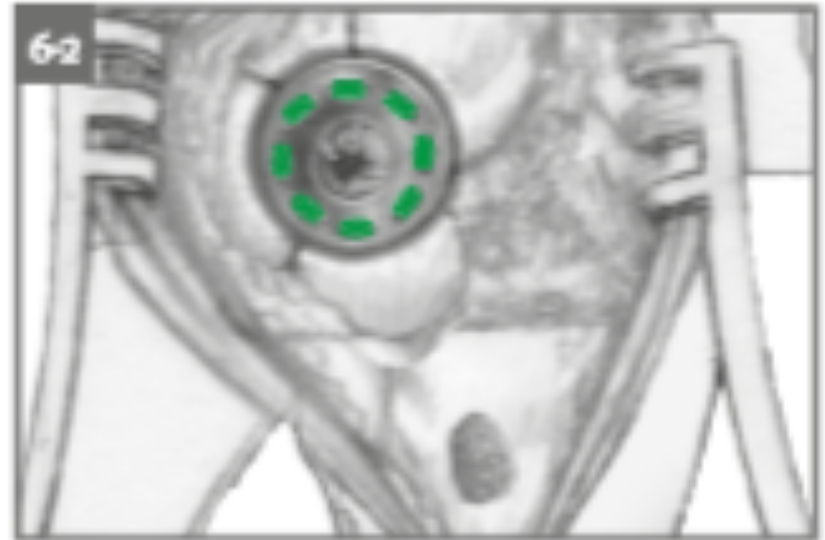
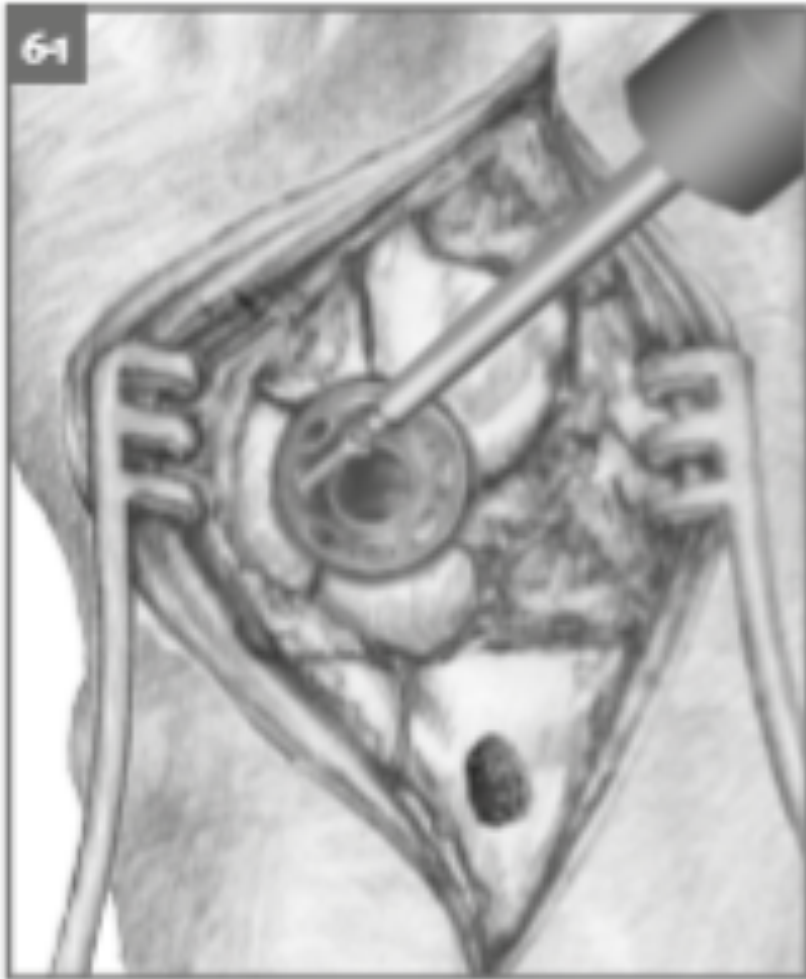

# TECHNIQUES

24



# TECHNIQUES



# TECHNIQUES

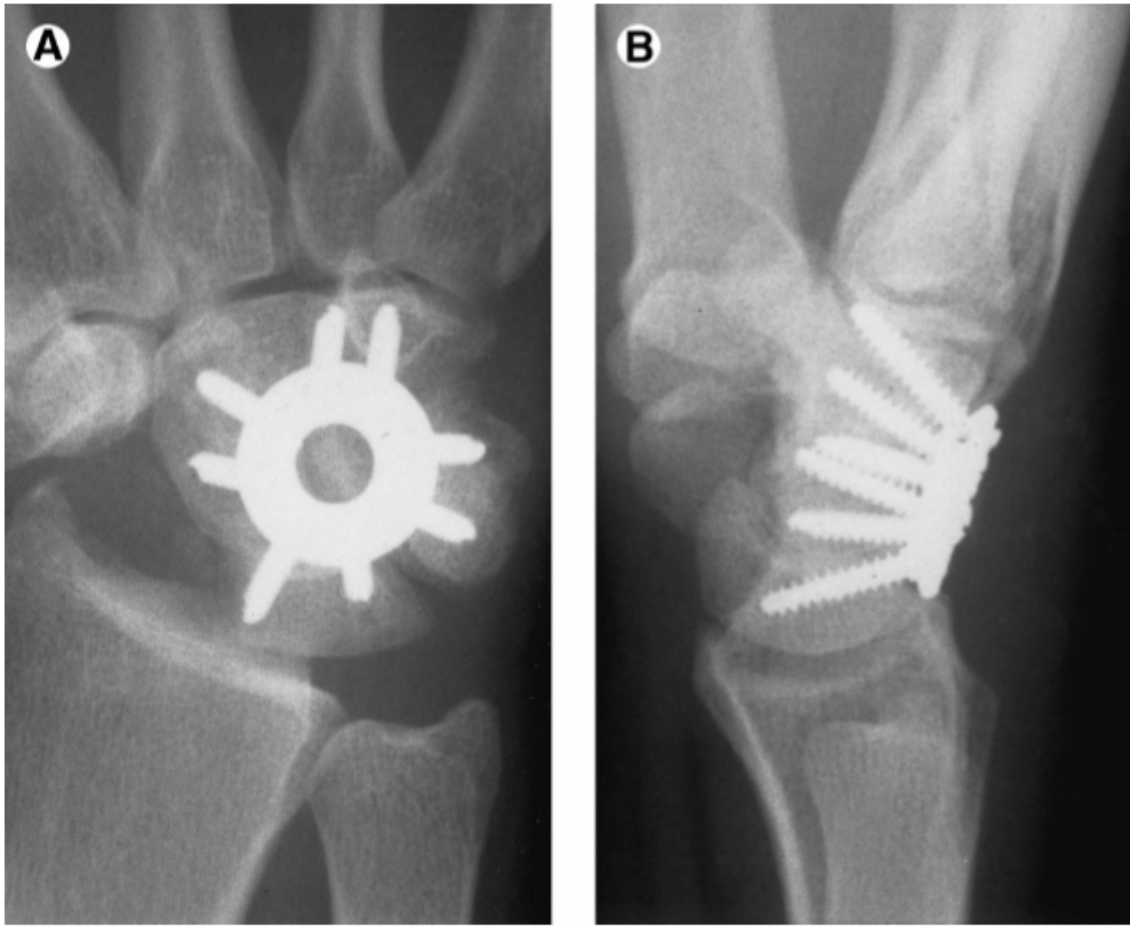
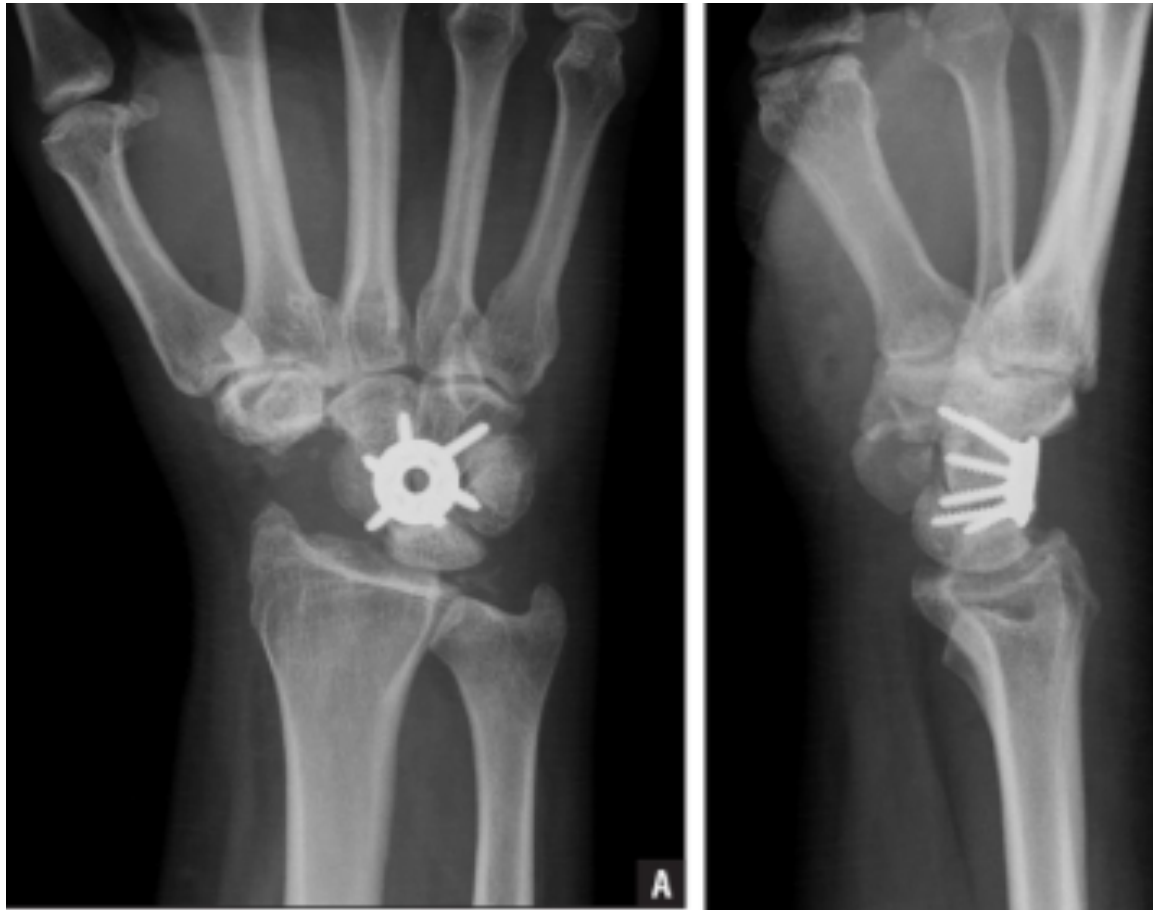

FIGURE 16. (A, B) After the plate is applied and provisional fixation is removed, radiographs of the wrist are obtained. The radiographs of the Spider plate for which the intraoperative photographs are illustrated in Figures 13, 14, and 15 are shown here.

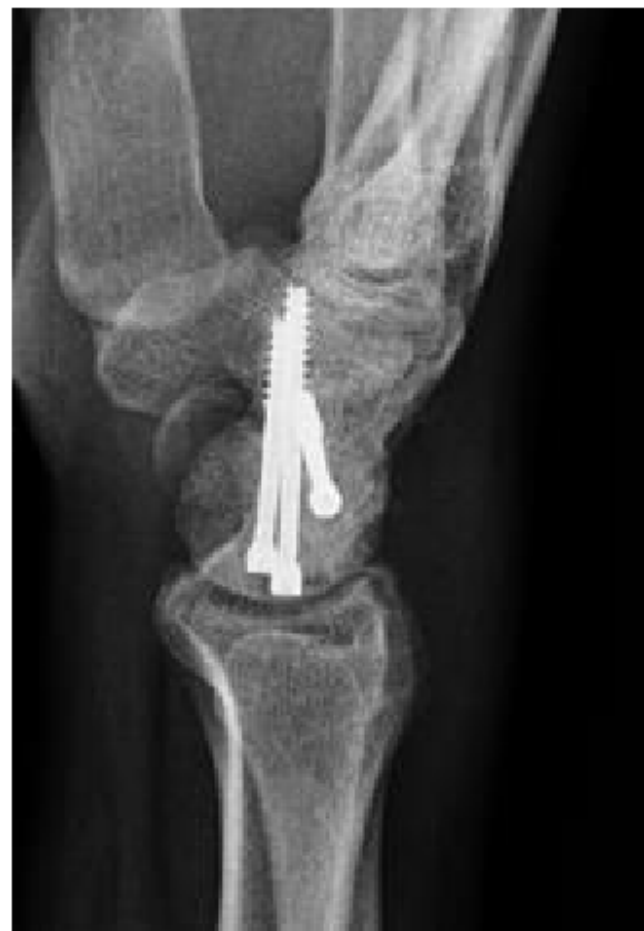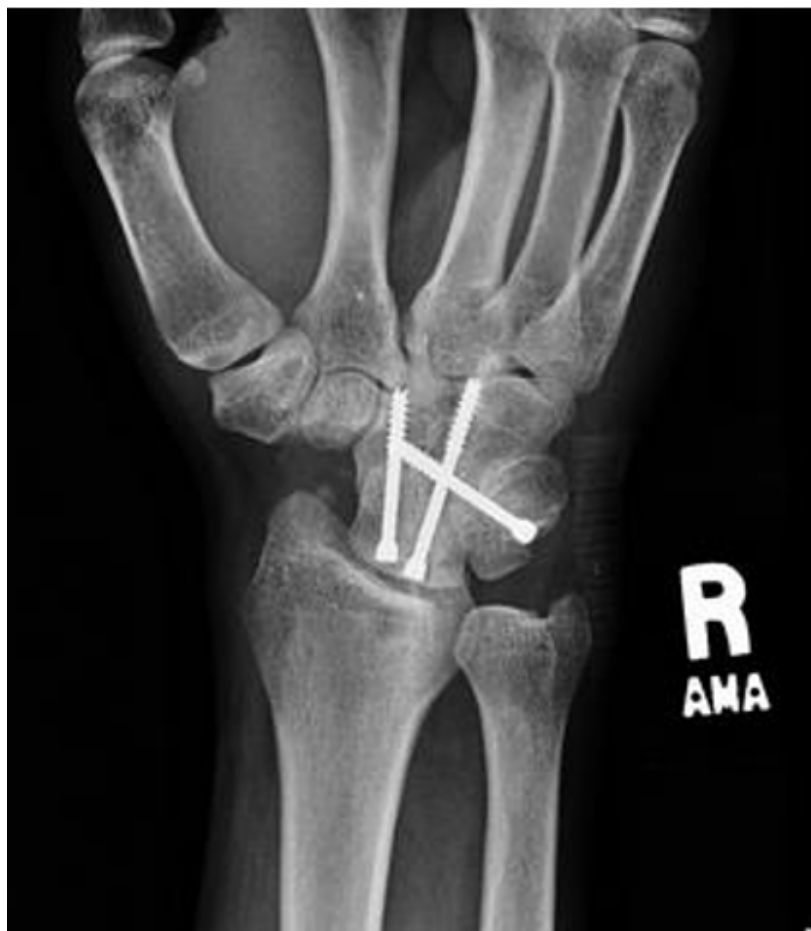# TECHNIQUES



# TECHNIQUES



# TECHNIQUES



***Thank you for your attention!***

