

PELVIC RESECTIONS – A CASE REPORT

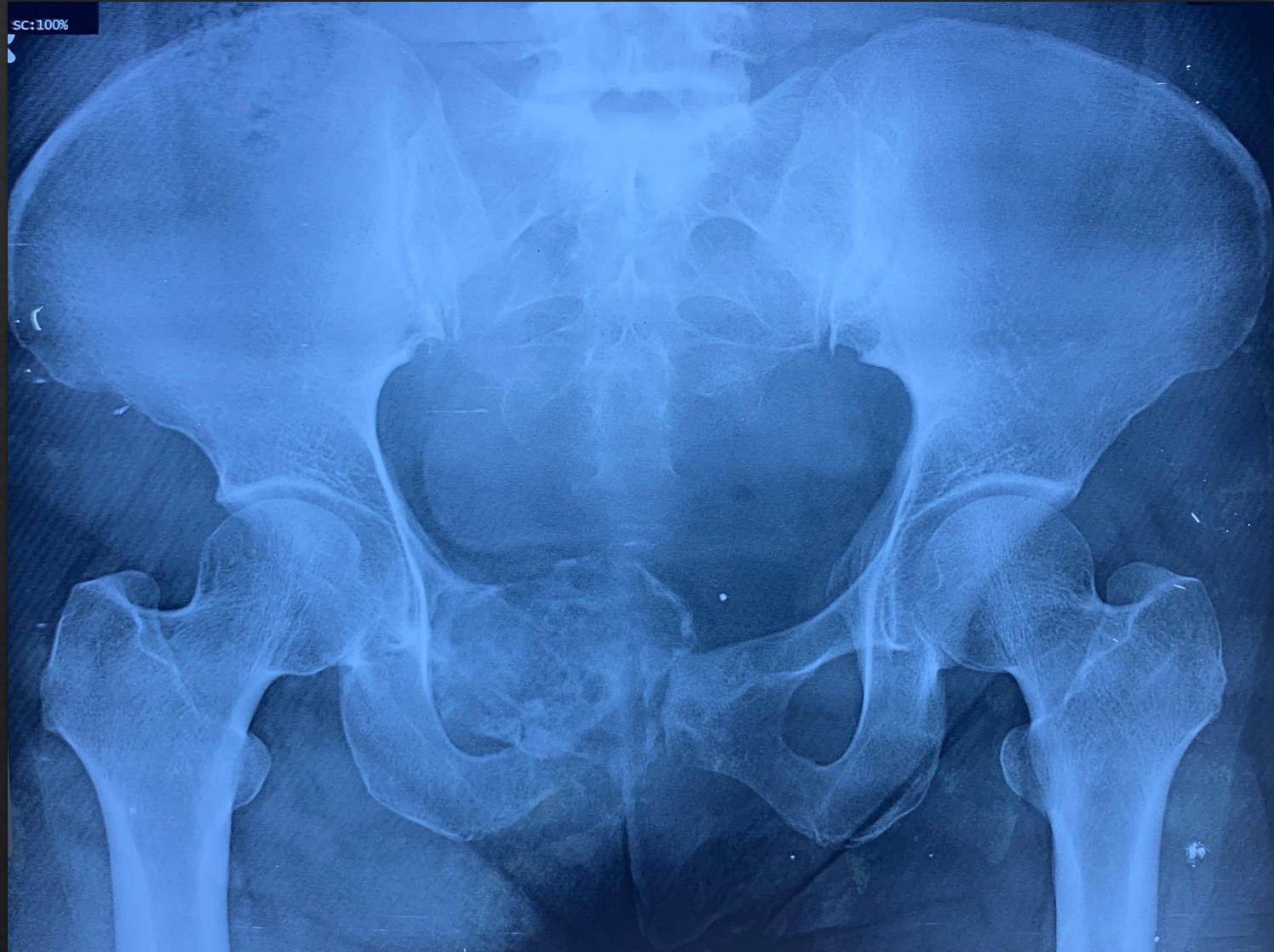
Le Van Tho, PhD, MD
Ngo Viet Nhuan, MD

Dec – 2020

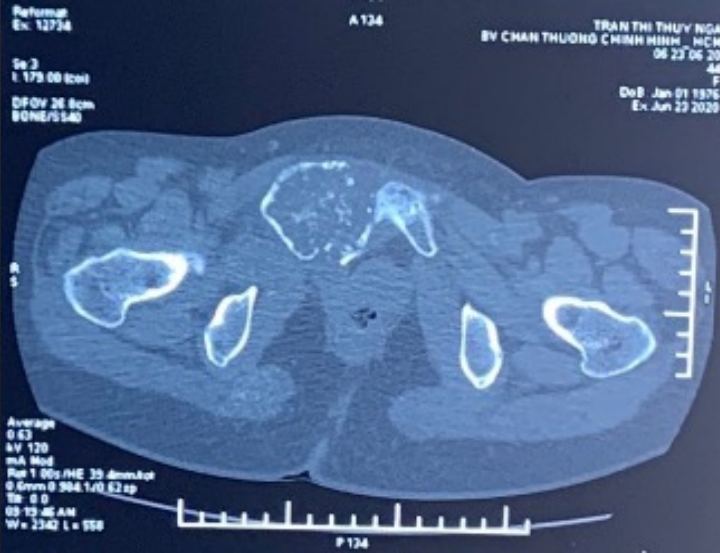
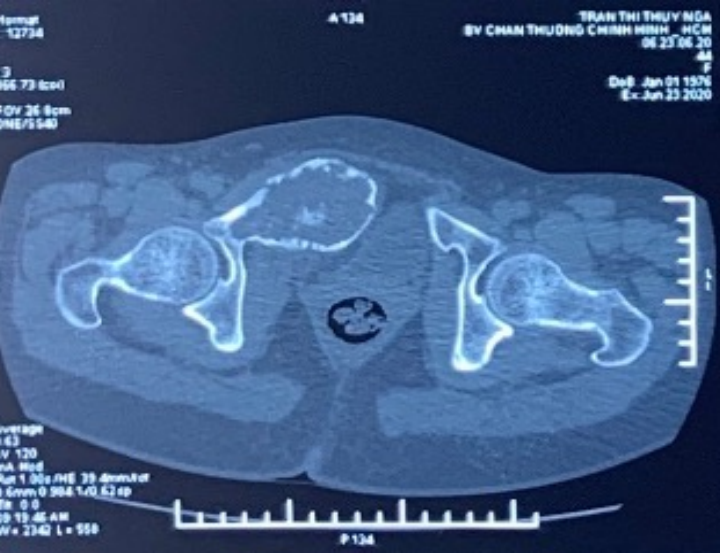
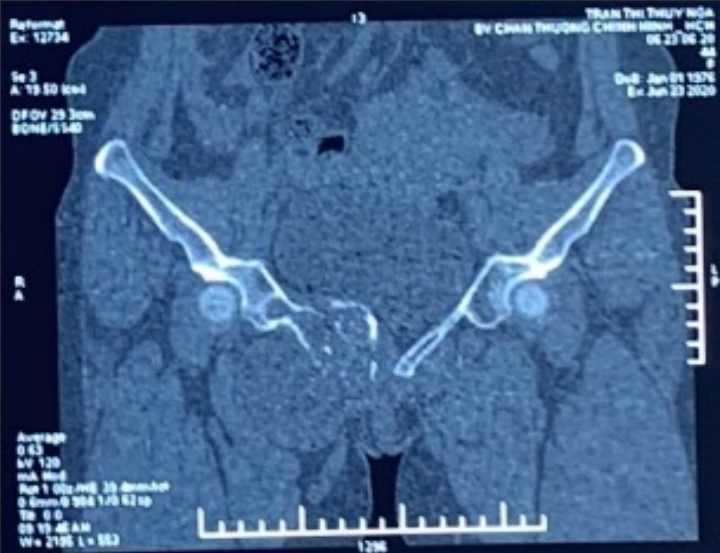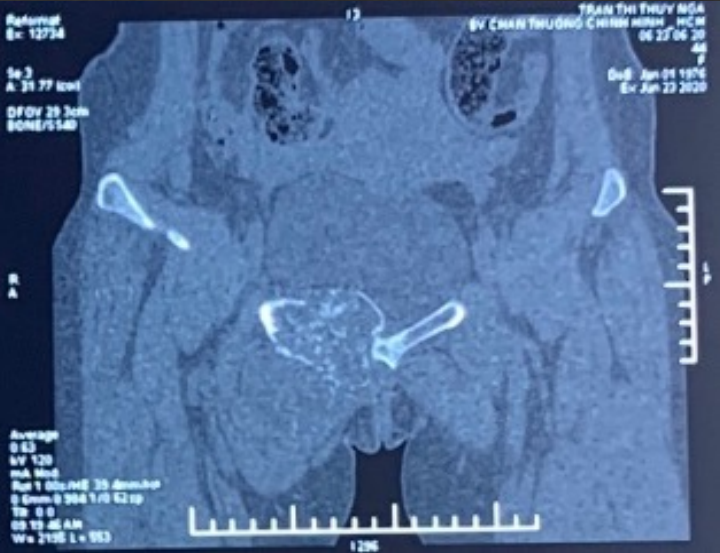Case Presentation

- ◇ 48 yo woman
- ◇ History of illness:
 - ◇ Large mass of R pubic region
 - ◇ No history of trauma
- ◇ Physical examination:
 - ◇ Mass: 10x15 cm, immobile, hard and tenderness
 - ◇ Neurovascular intact
 - ◇ R Hip ROM normal

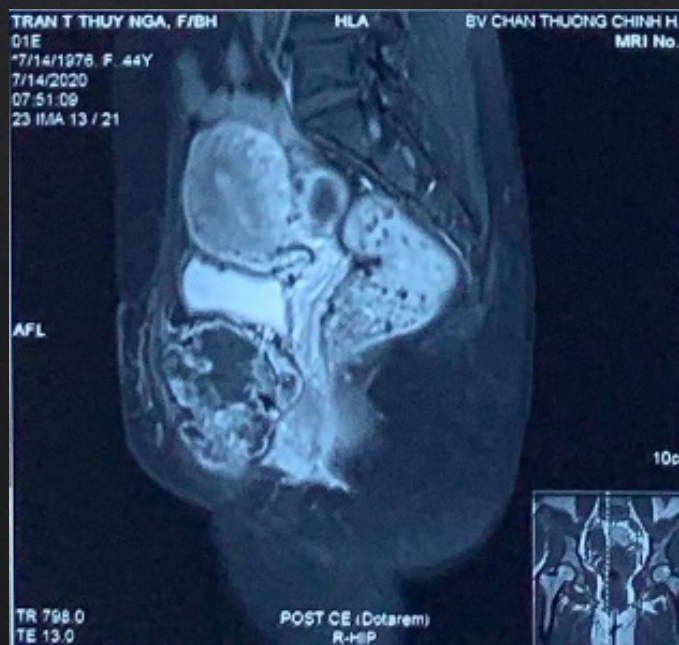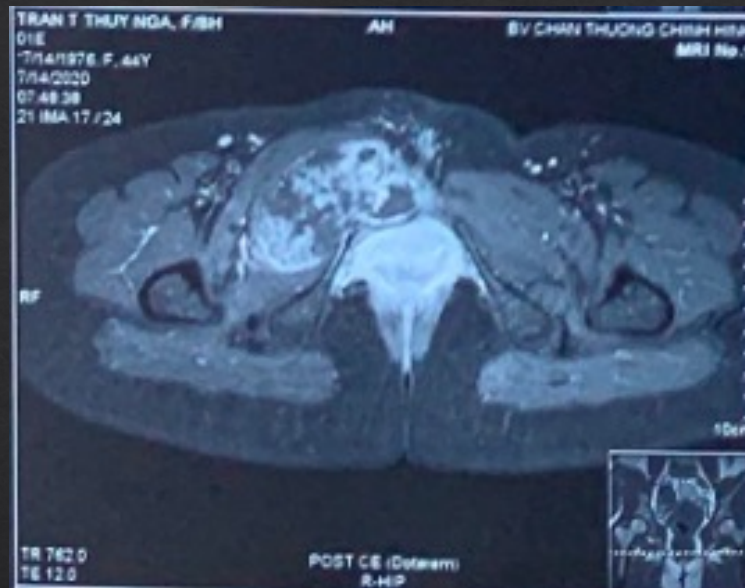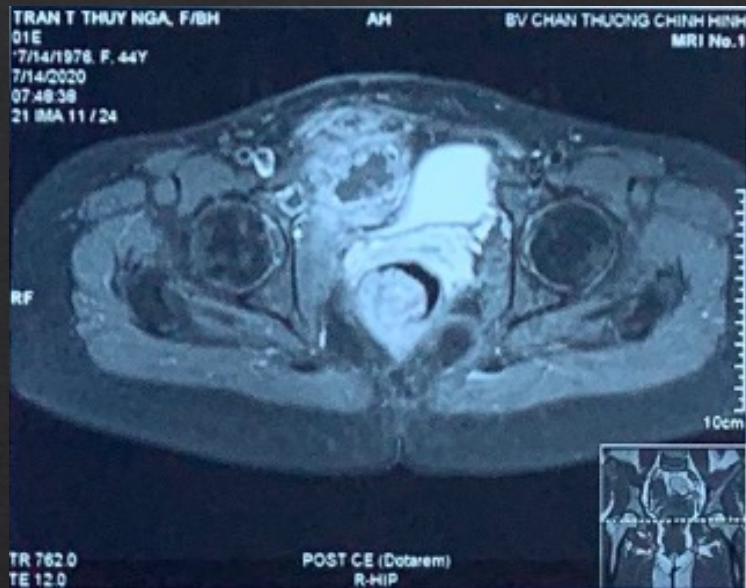PreOp Xray



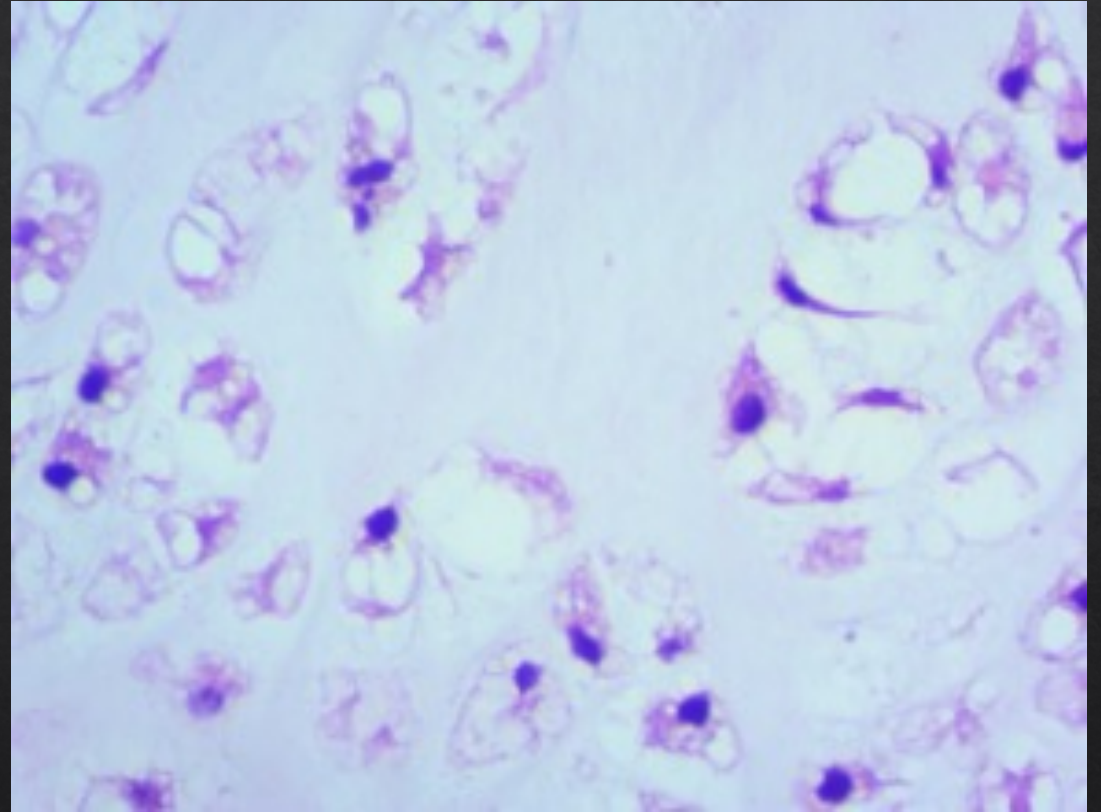
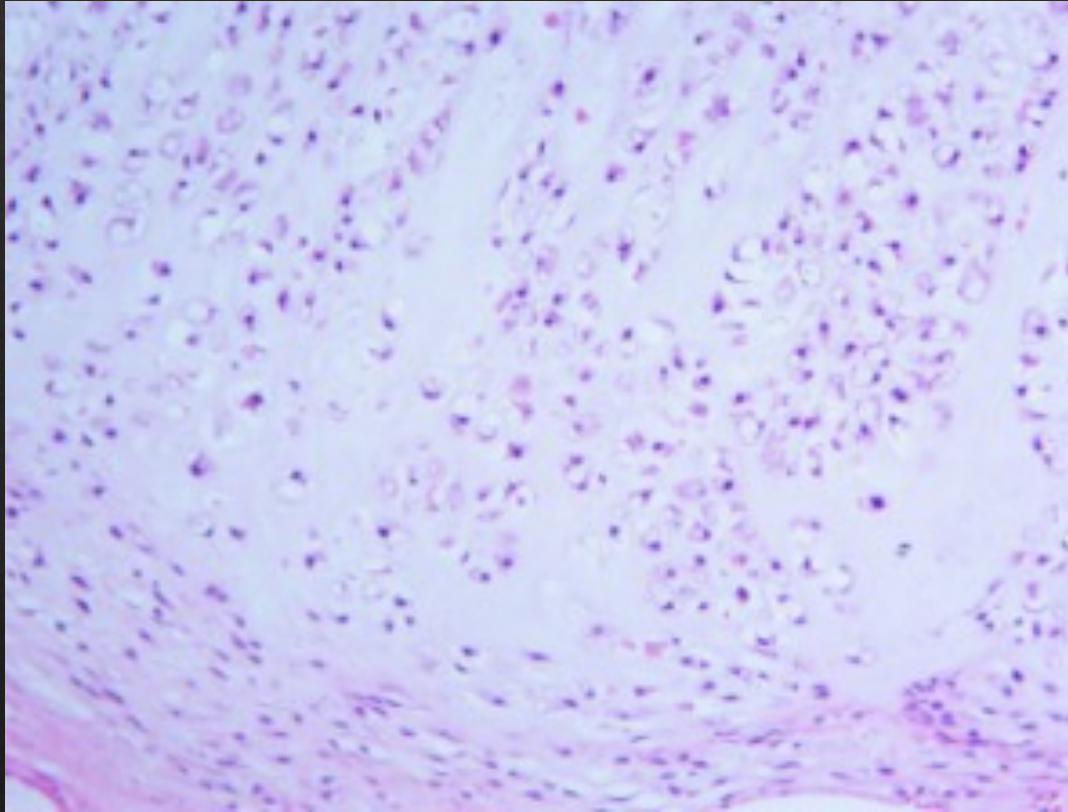
CTscan



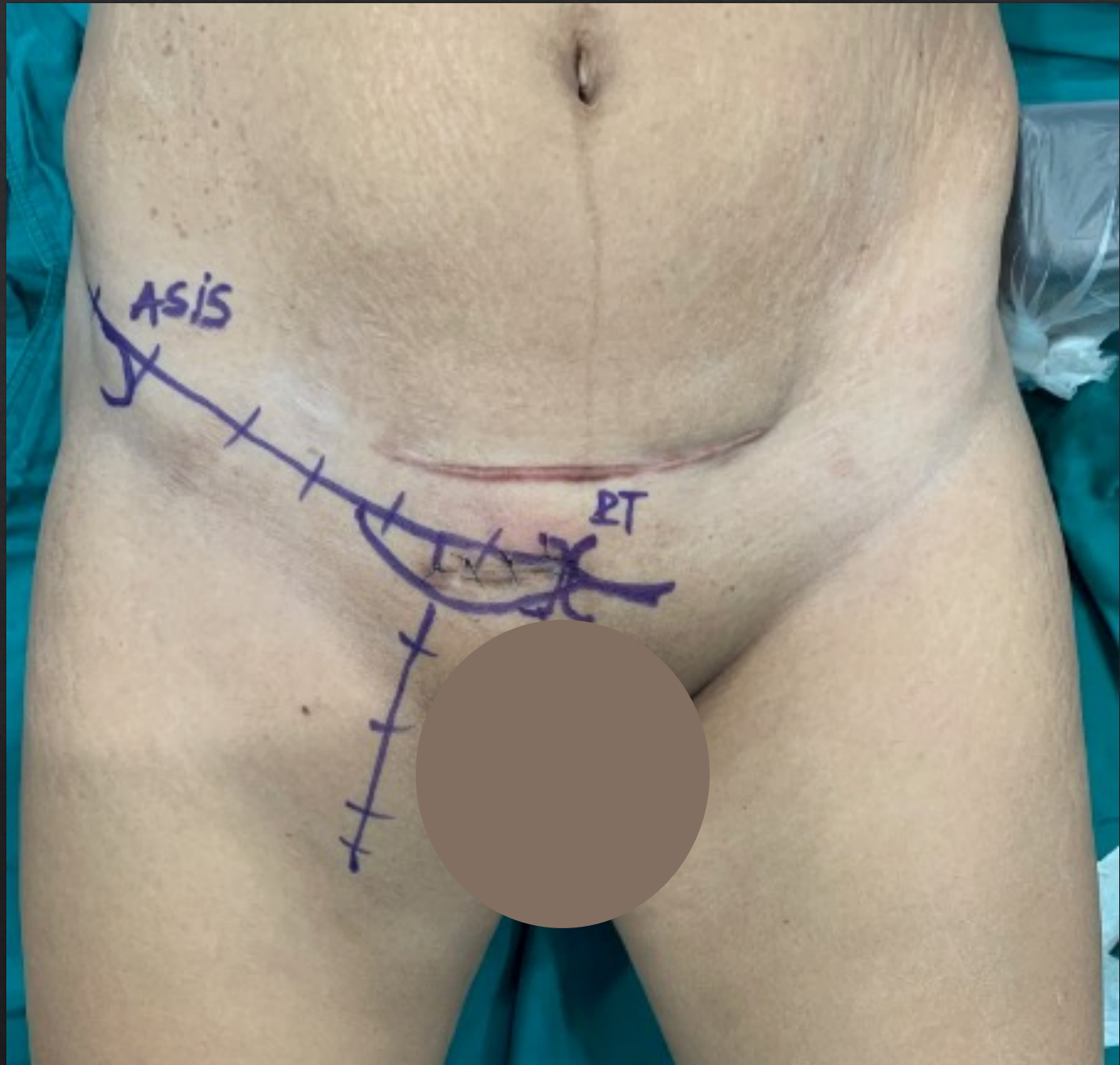
MRI



Diagnostic Pathology

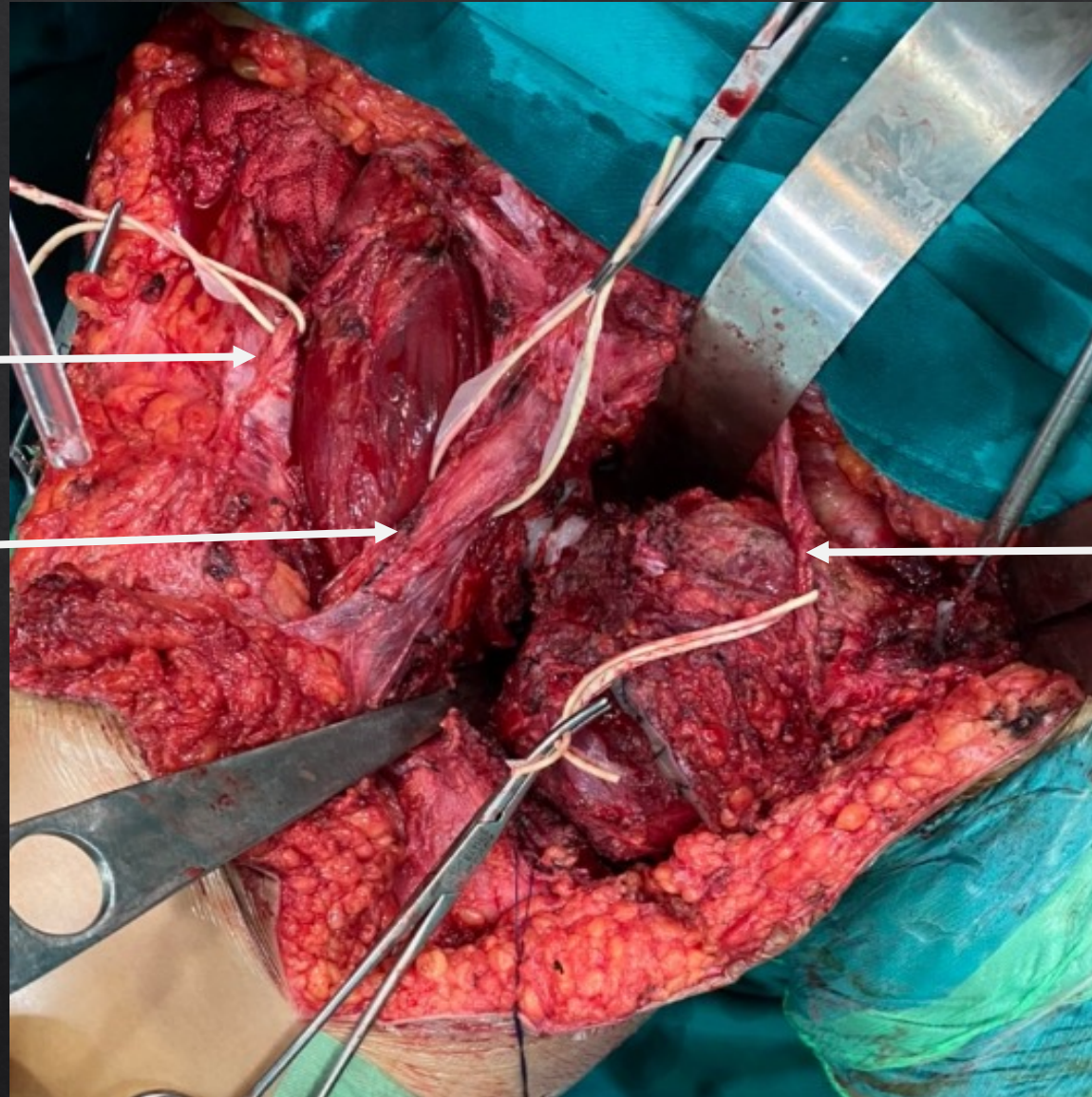


Well-Differentiated Conventional Chondrosarcoma (Grade 1)



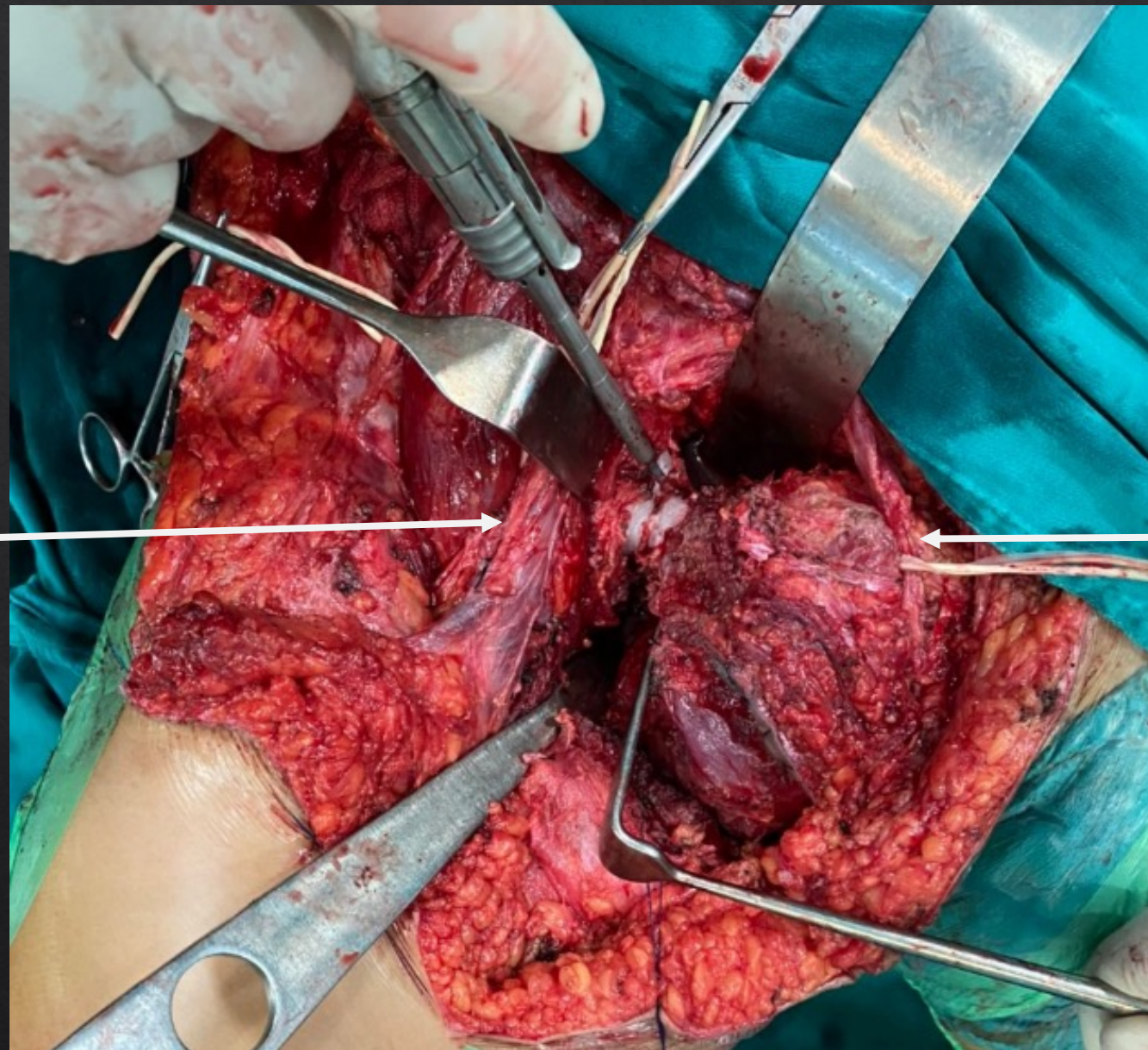
Lateral femoral cutaneous nerve

Femoral neurovascular bundle

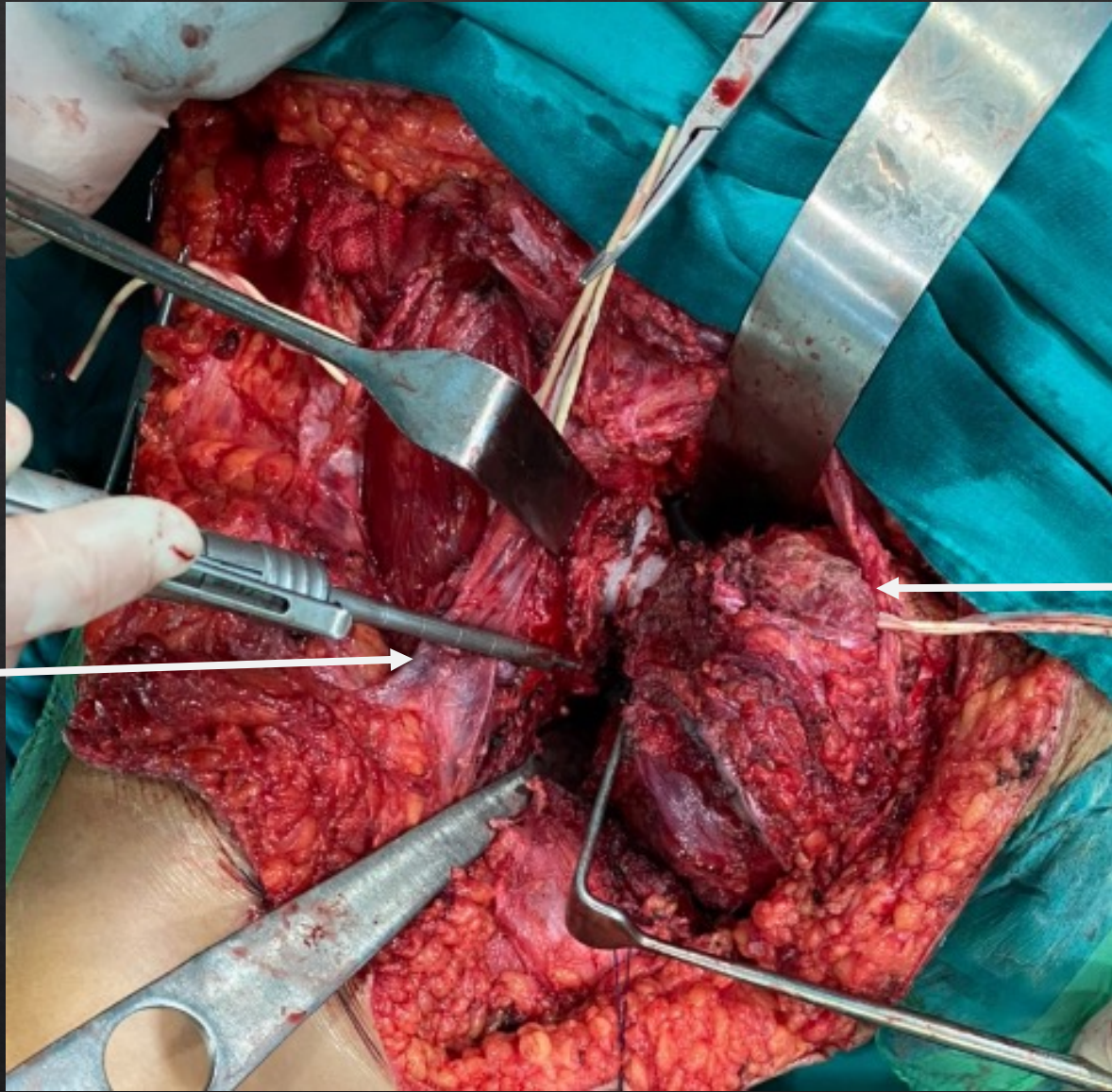


Round ligament

**Femoral
neurovascular bundle**



Round ligament




**Femoral
neurovascular bundle**



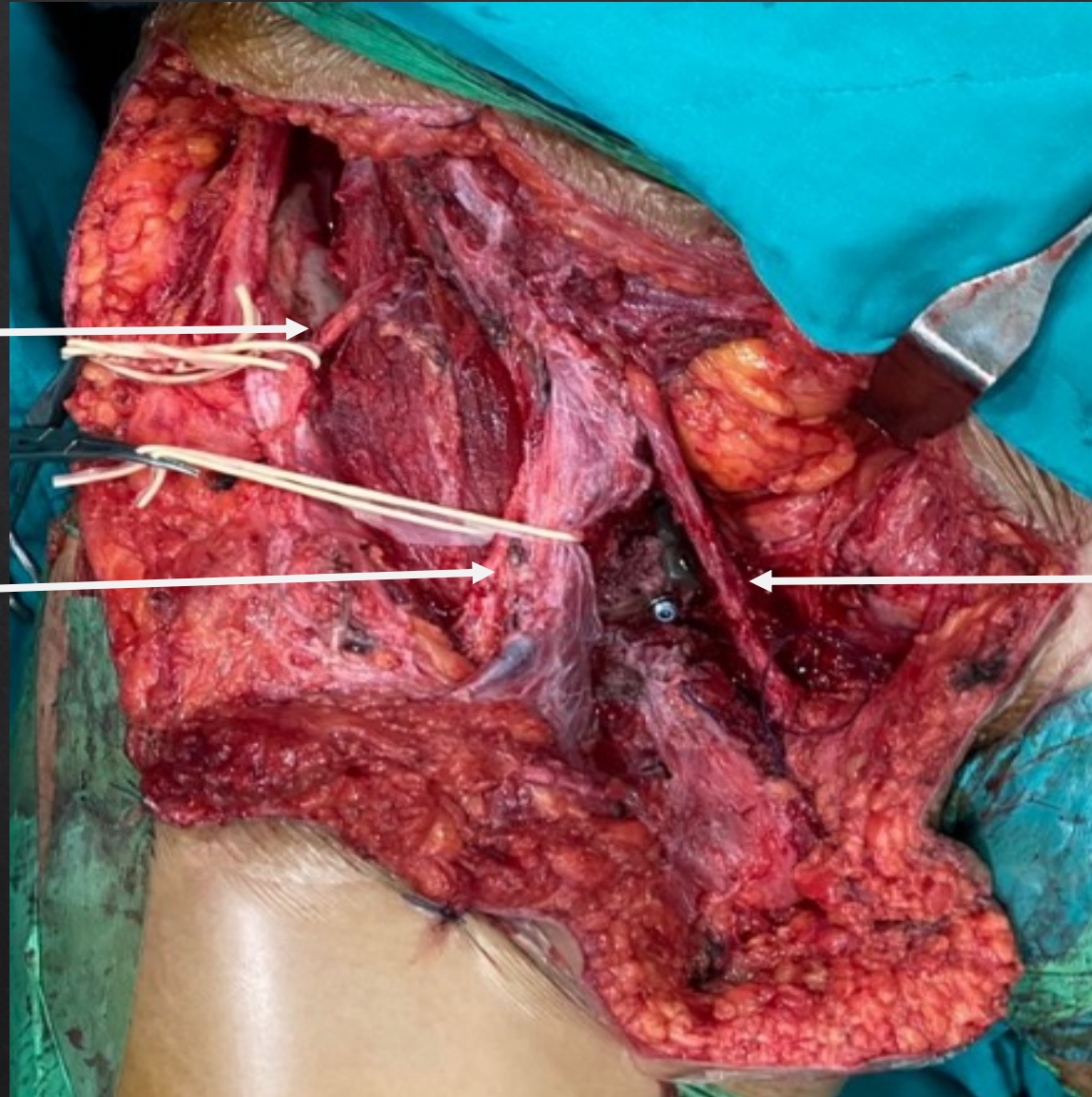
Round ligament



Lateral femoral cutaneous nerve



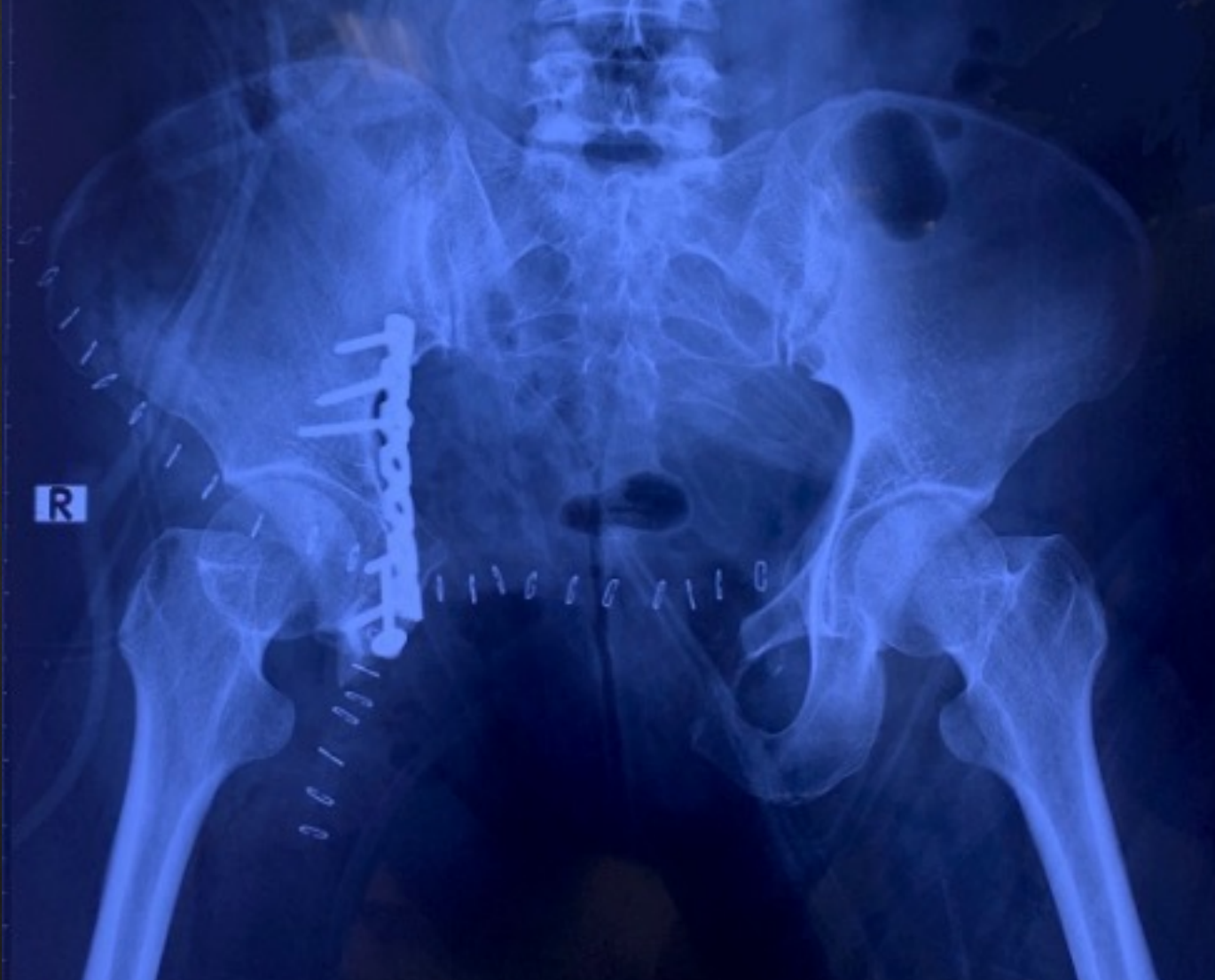Femoral neurovascular bundle



Round ligament



PostOp Xray



Operating time: 7 hours

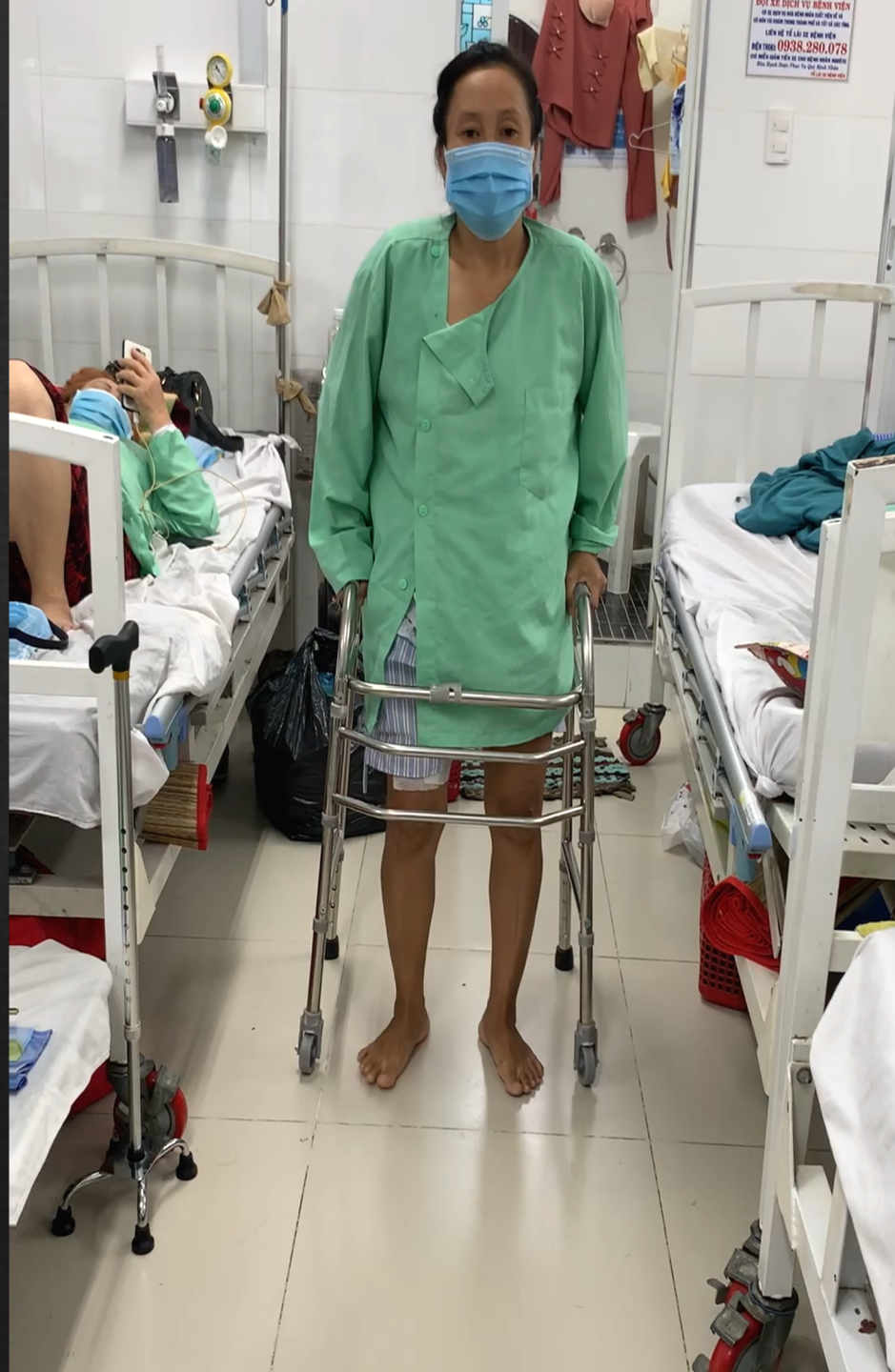Blood loss: 1500ml

Blood transfusions:

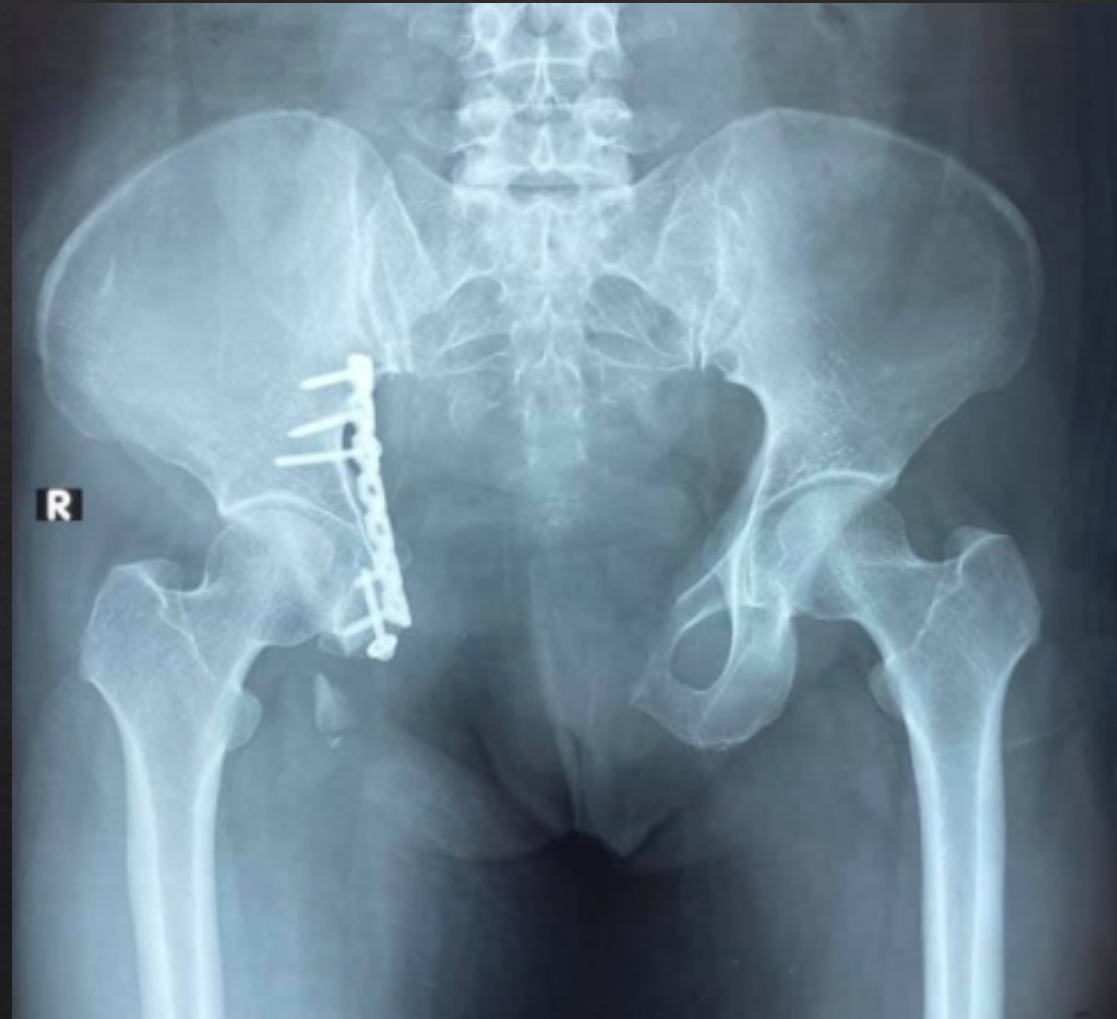Red blood cell: 8 units

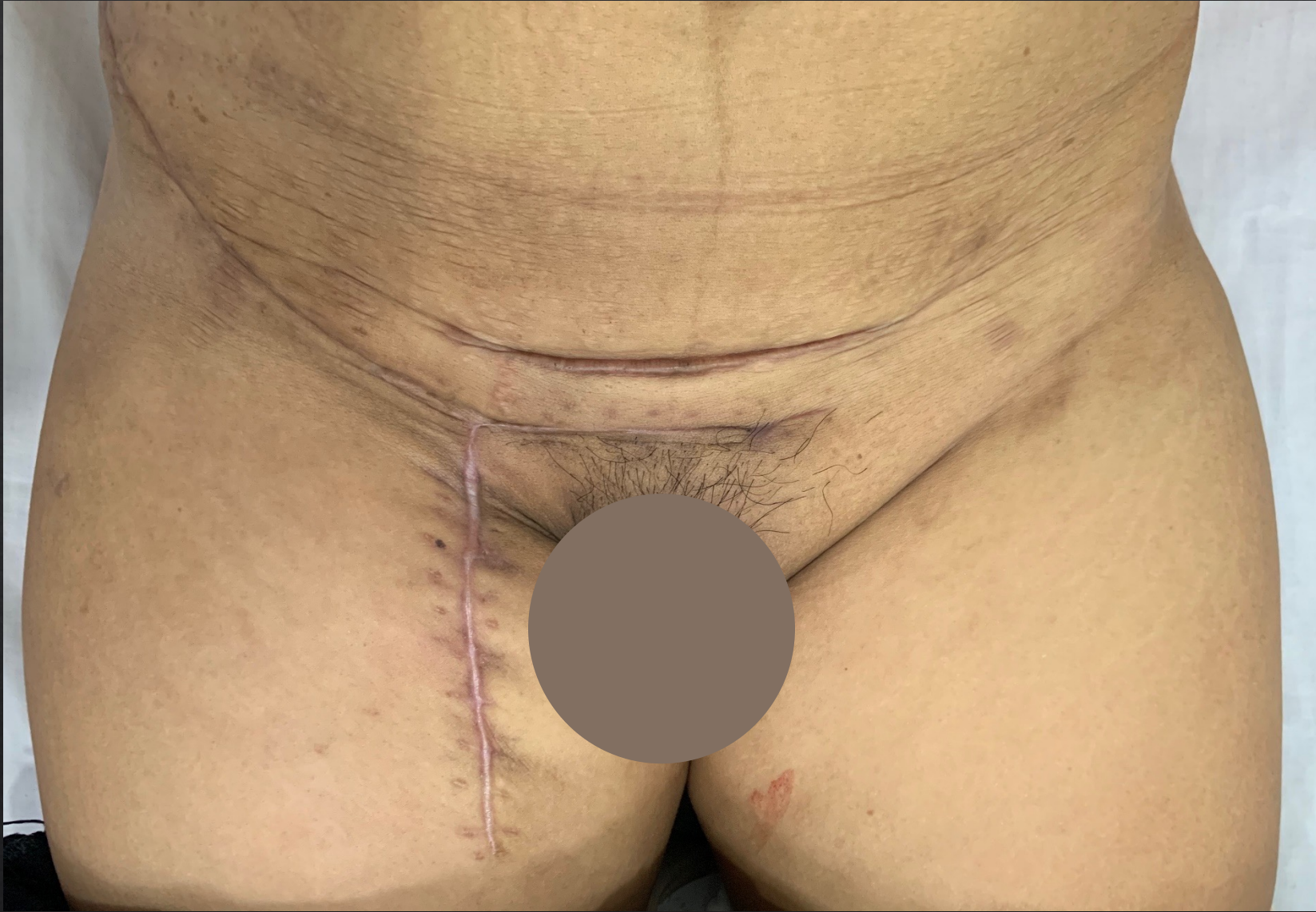Plasma: 2 unit

PostOp 1 week



PostOp 8 weeks Xray





PostOp 8 weeks



PostOp 8 weeks

Discussion

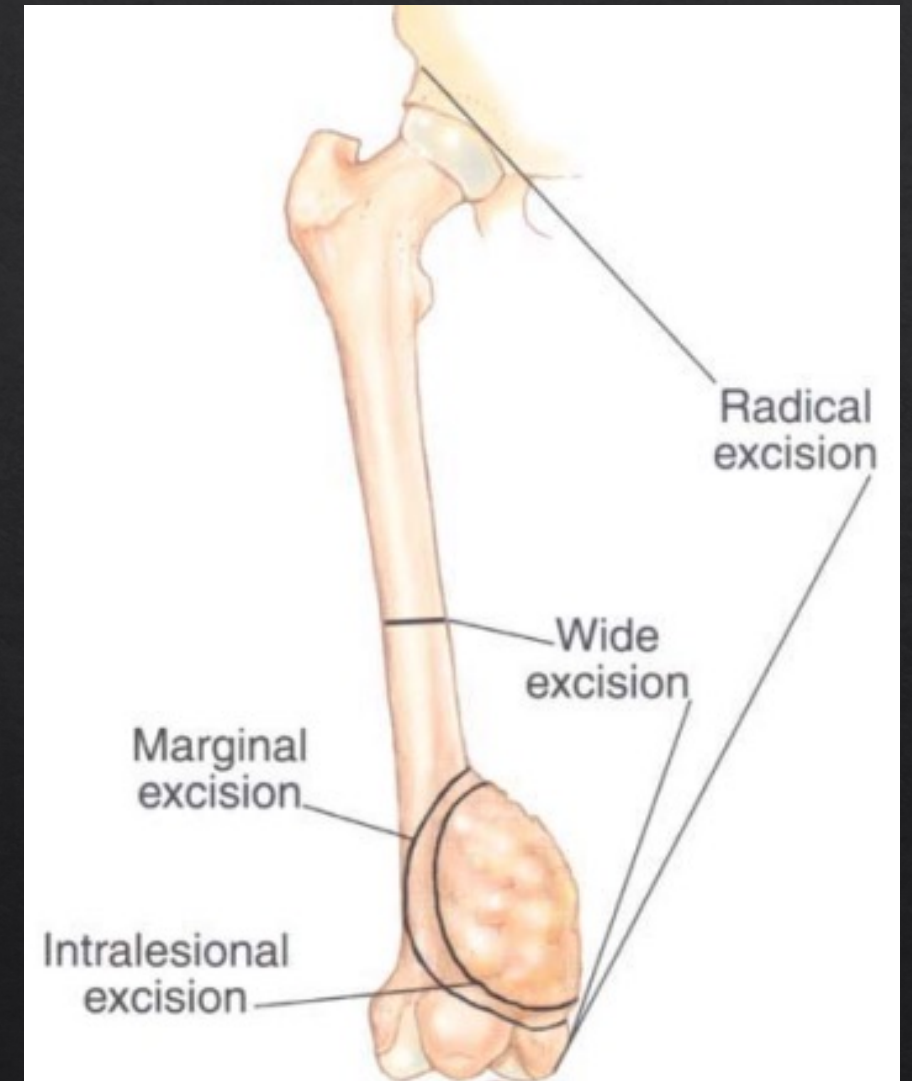
- ◆ Surgical margins
- ◆ Reconstruction

Conventional Chondrosarcoma

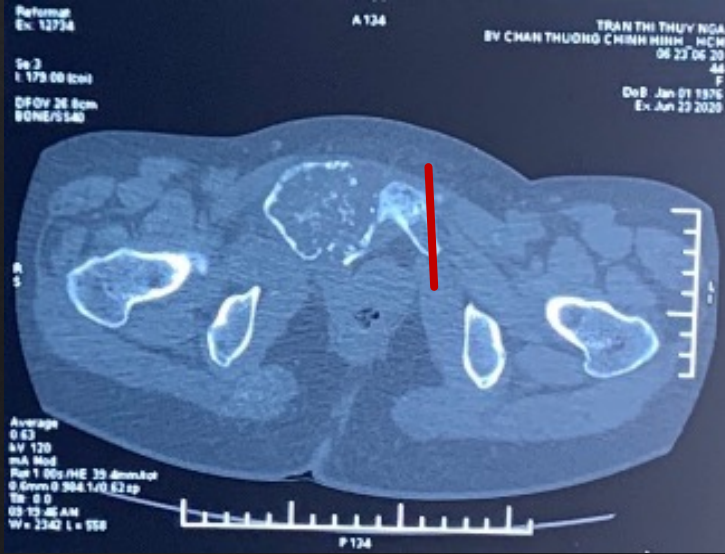
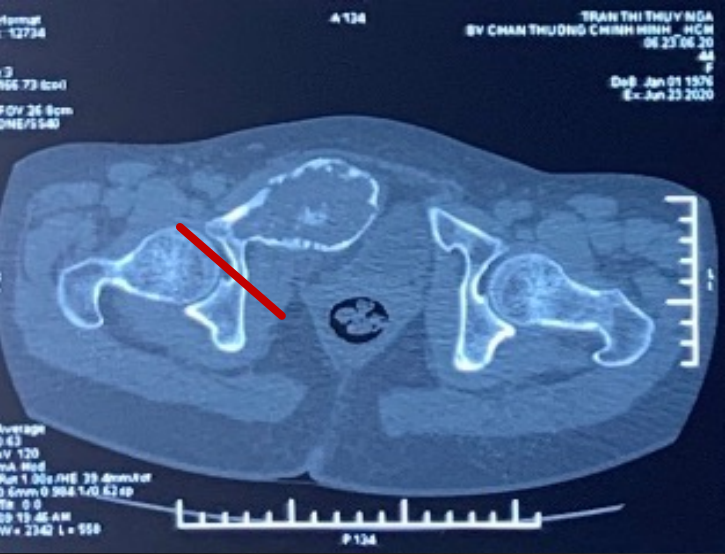
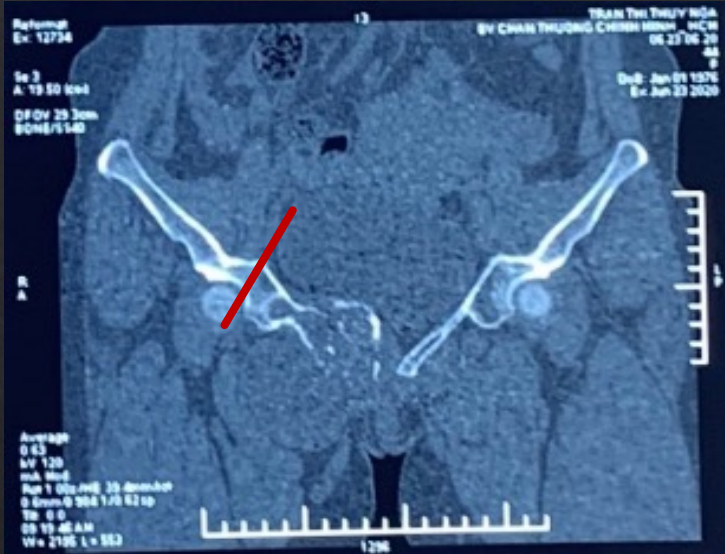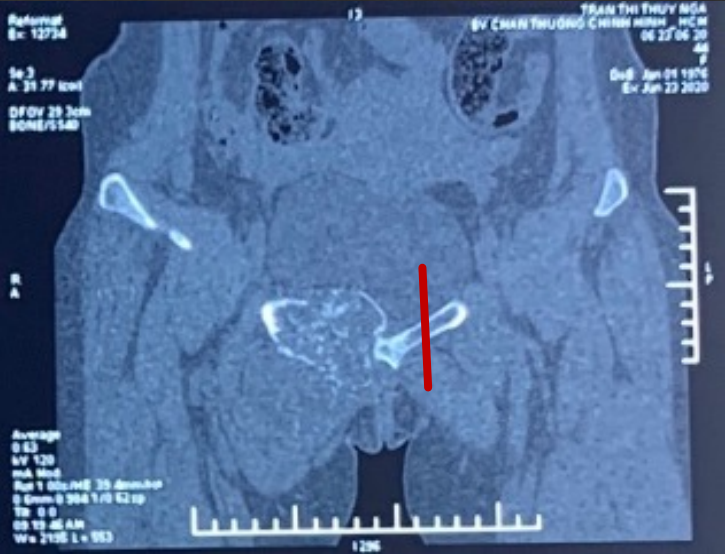- ◇ Malignant tumor of cartilage – matrix formed is uniformly and entirely chondroid
- ◇ 3 grade: low, intermediate, high
- ◇ Treatment:
 - ◇ Chemotherapy, radiotherapy: not sensitive
 - ◇ Surgical: effective treatment

Surgical margins

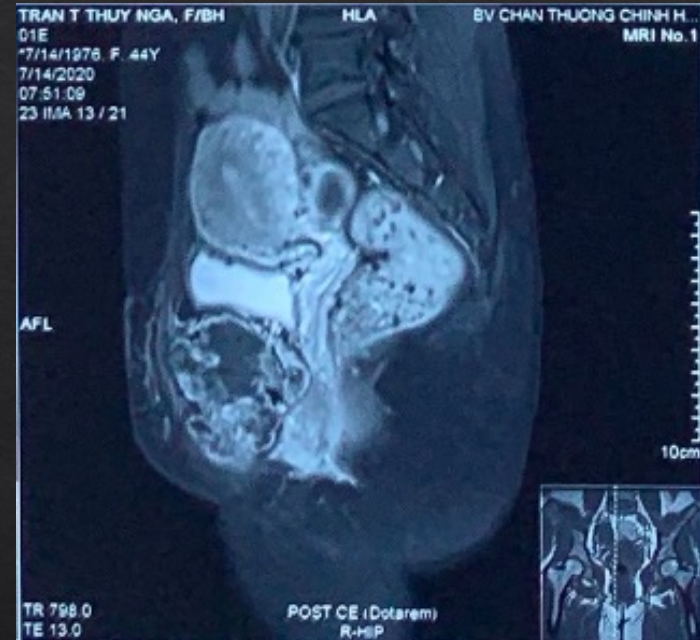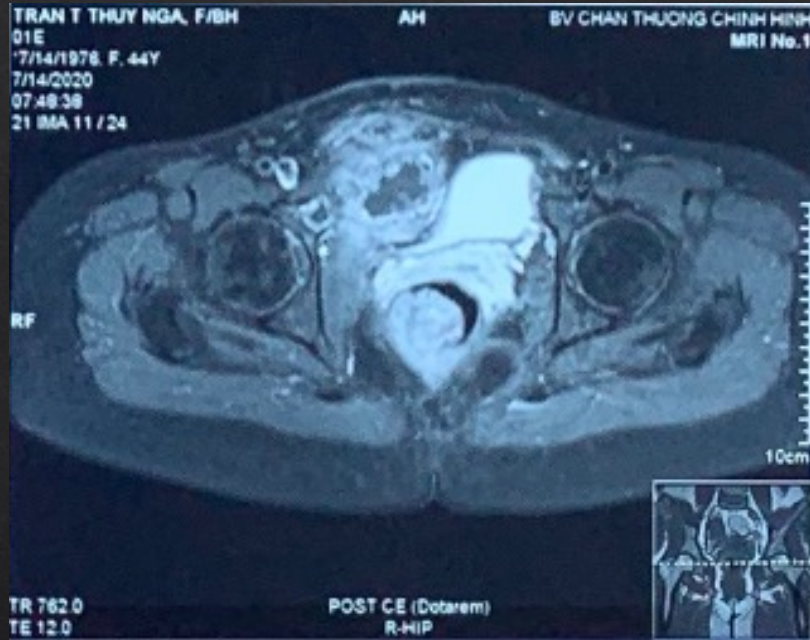
- ◆ Sarcoma:
 - ◆ Centrifugally growing
 - ◆ Reactive zone
- ◆ Surgical: Wide resections

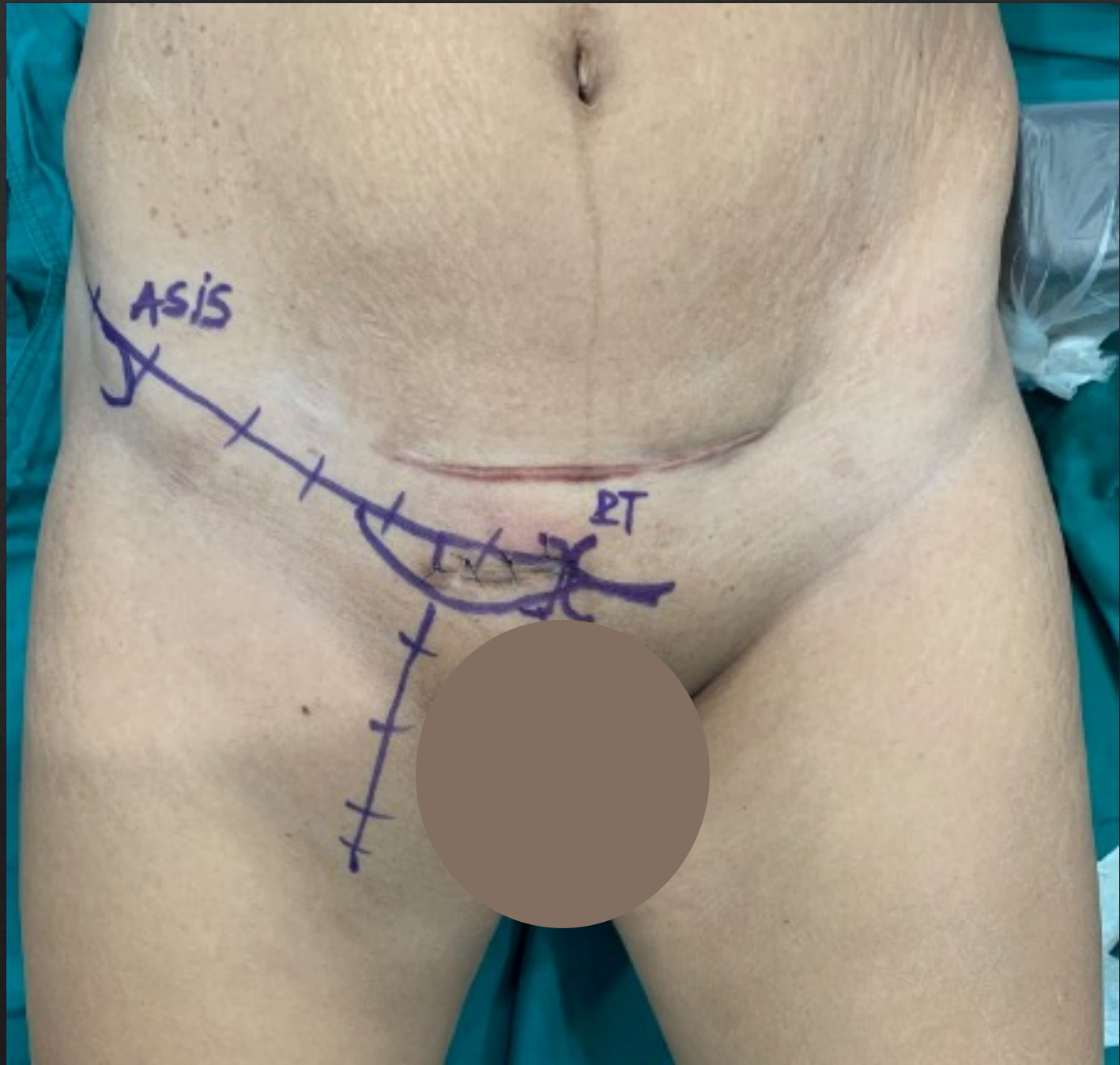


Surgical margins



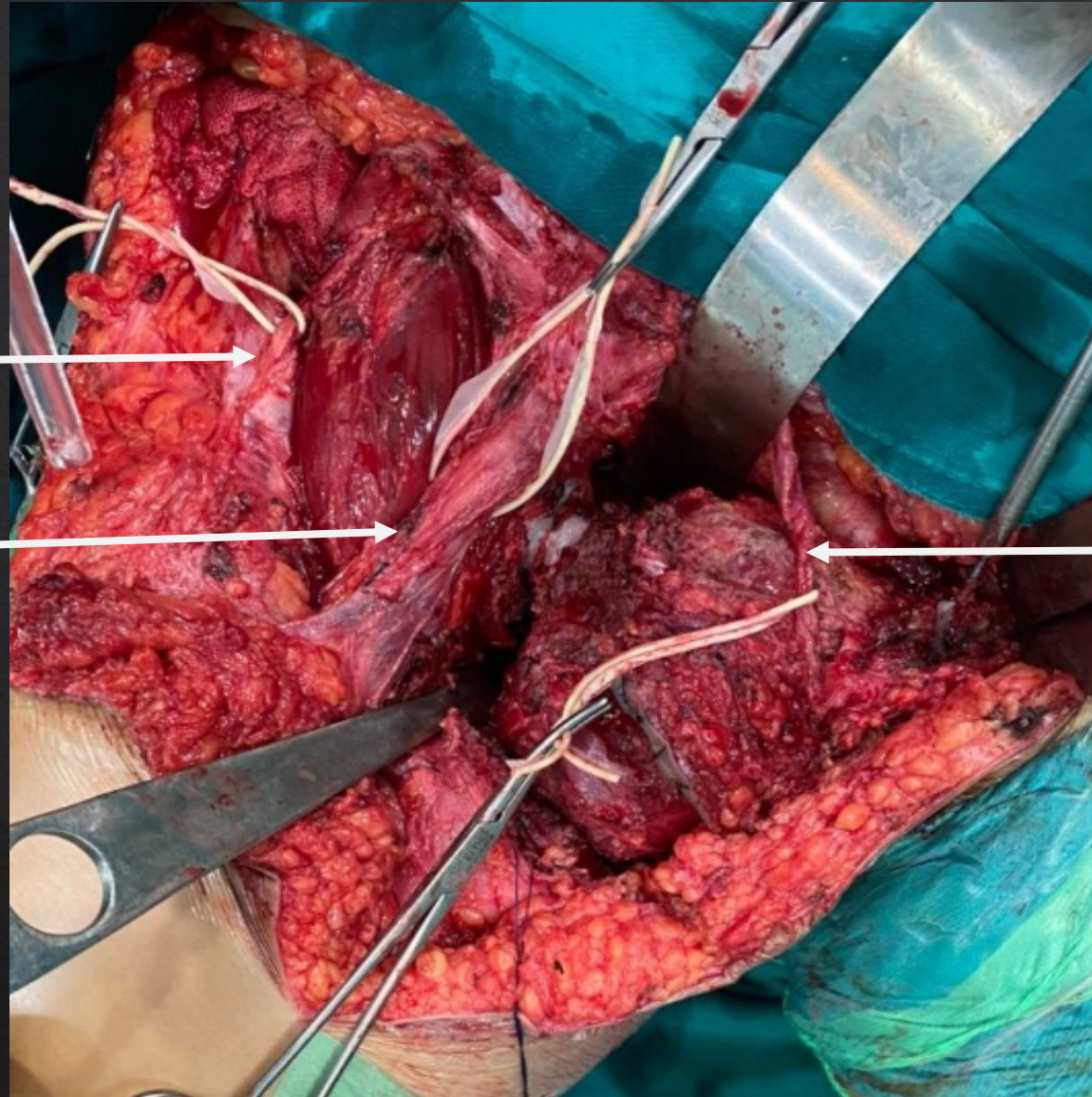
Surgical margins





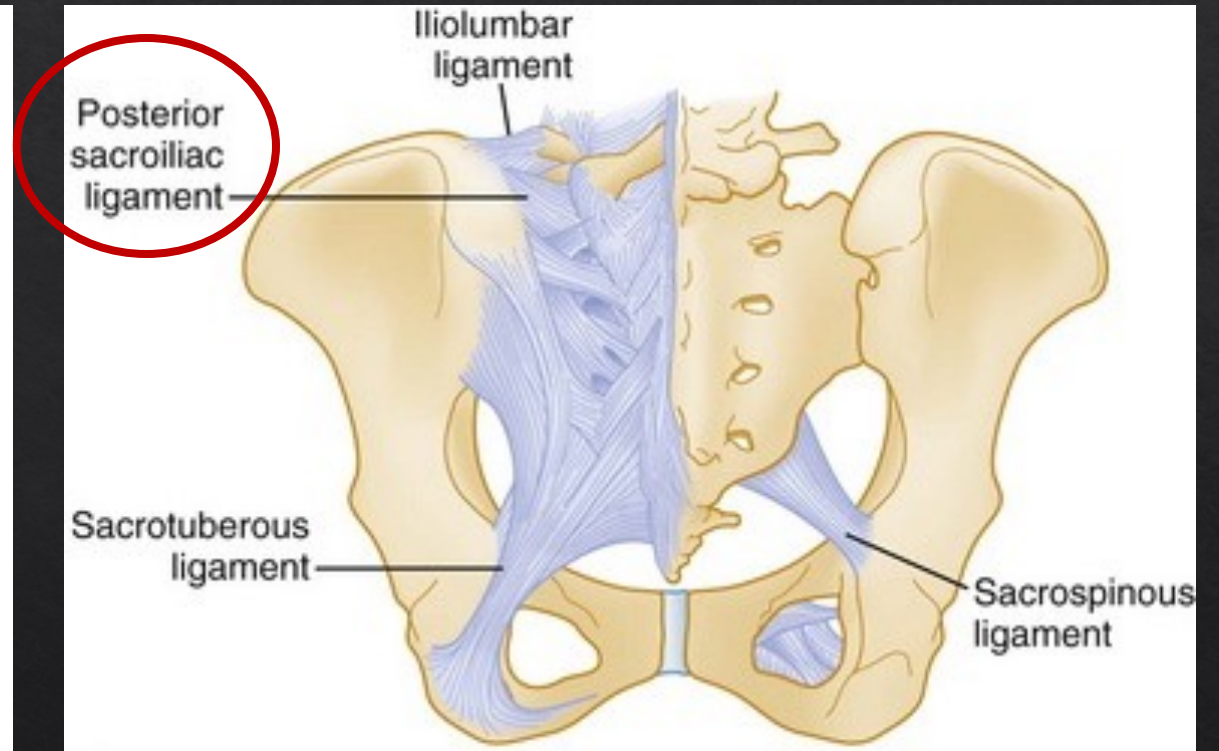
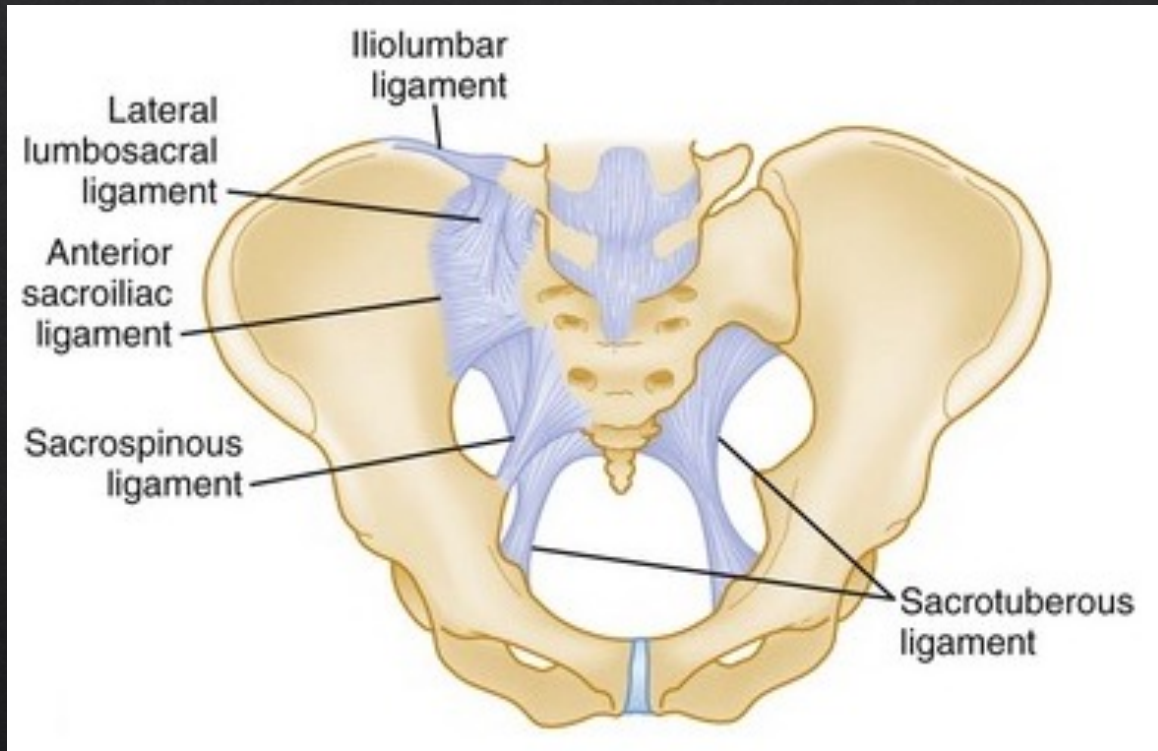
Lateral femoral cutaneous nerve

Femoral neurovascular bundle



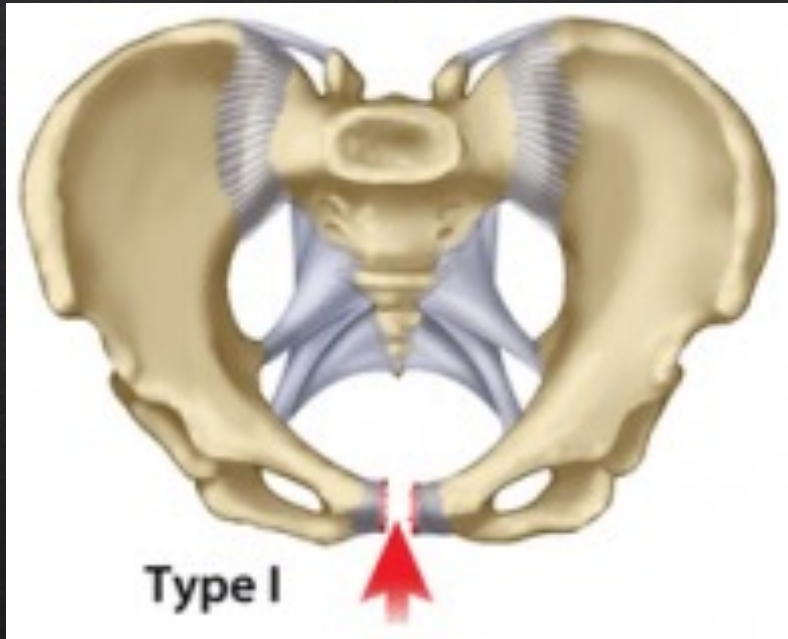
Round ligament

Reconstructions - Stability of pelvic rings

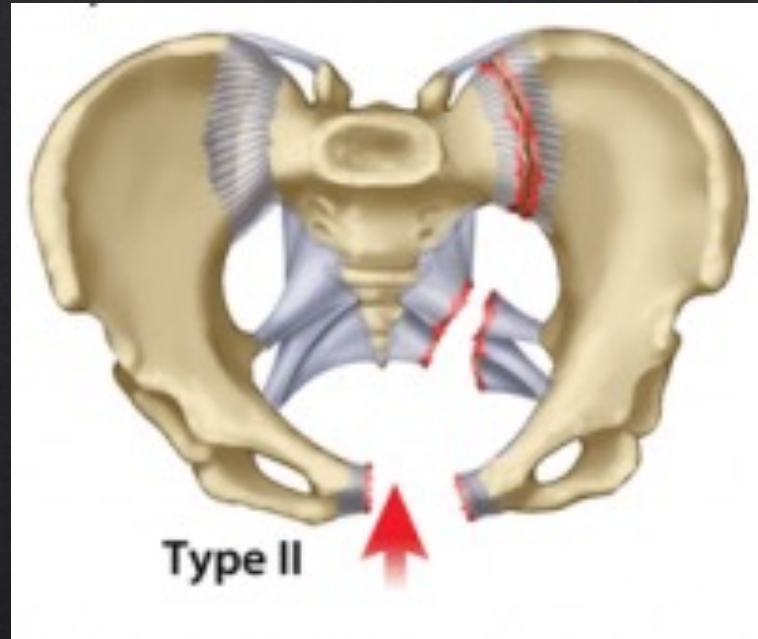


Ligaments of the pelvic ring

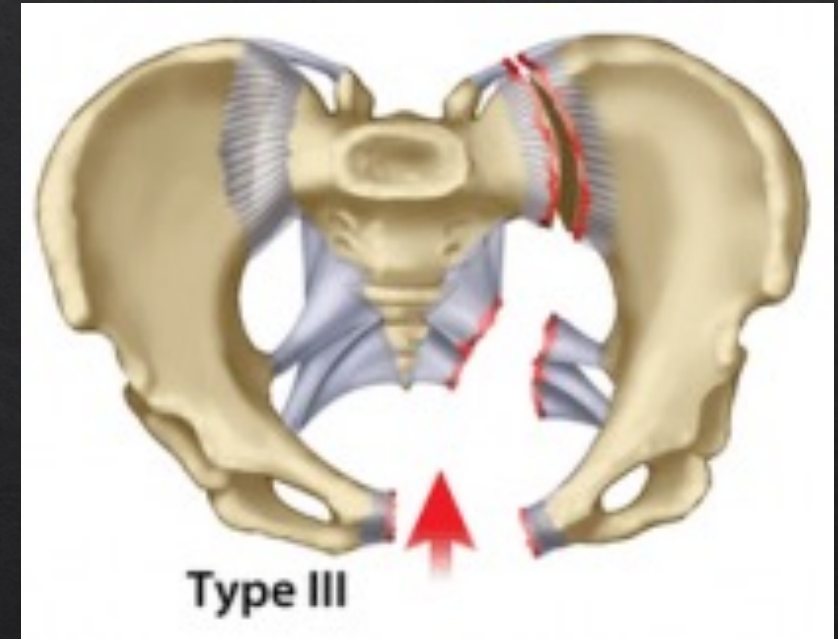
Reconstruction - Stability of pelvic rings



Stable



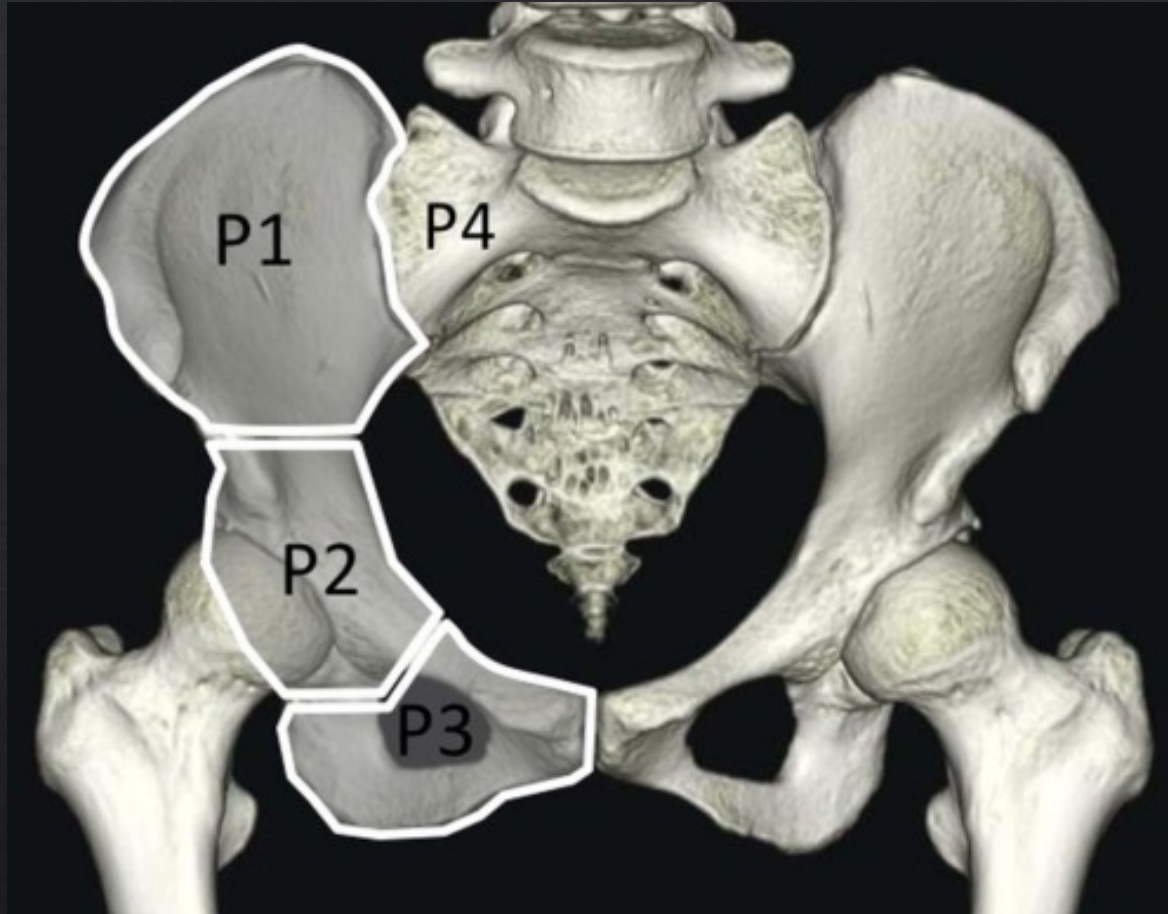
Incomplete Unstable



Complete Unstable

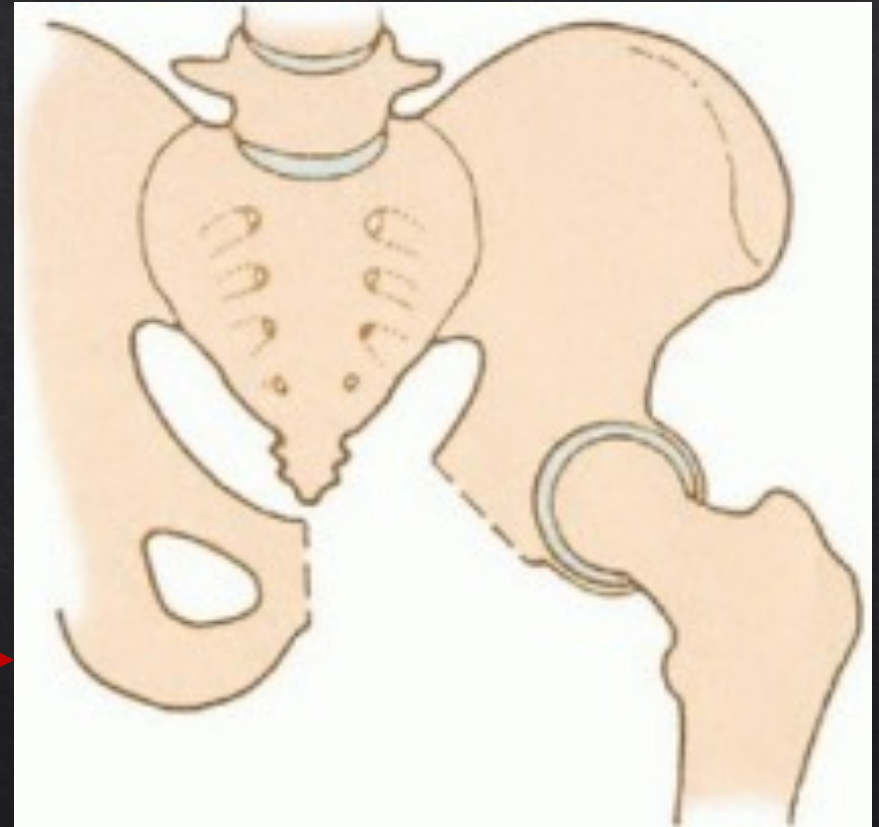
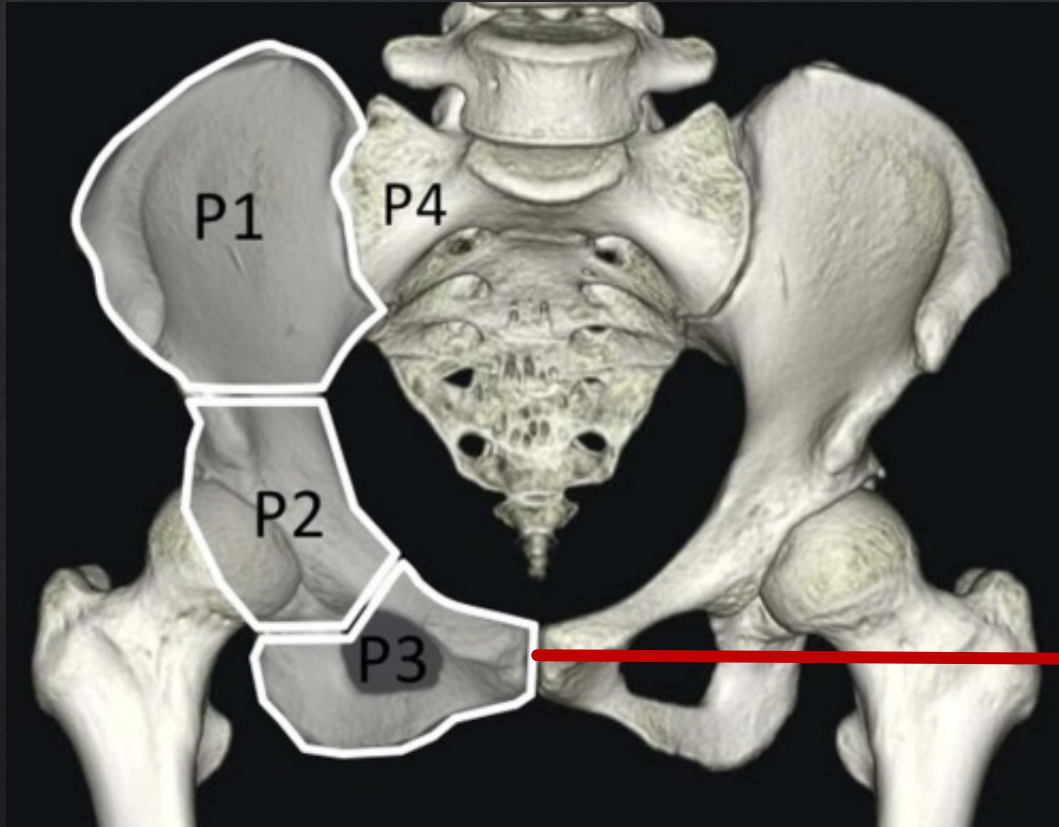
APC type – Young Burgess Pelvic Injury Classification

Reconstruction



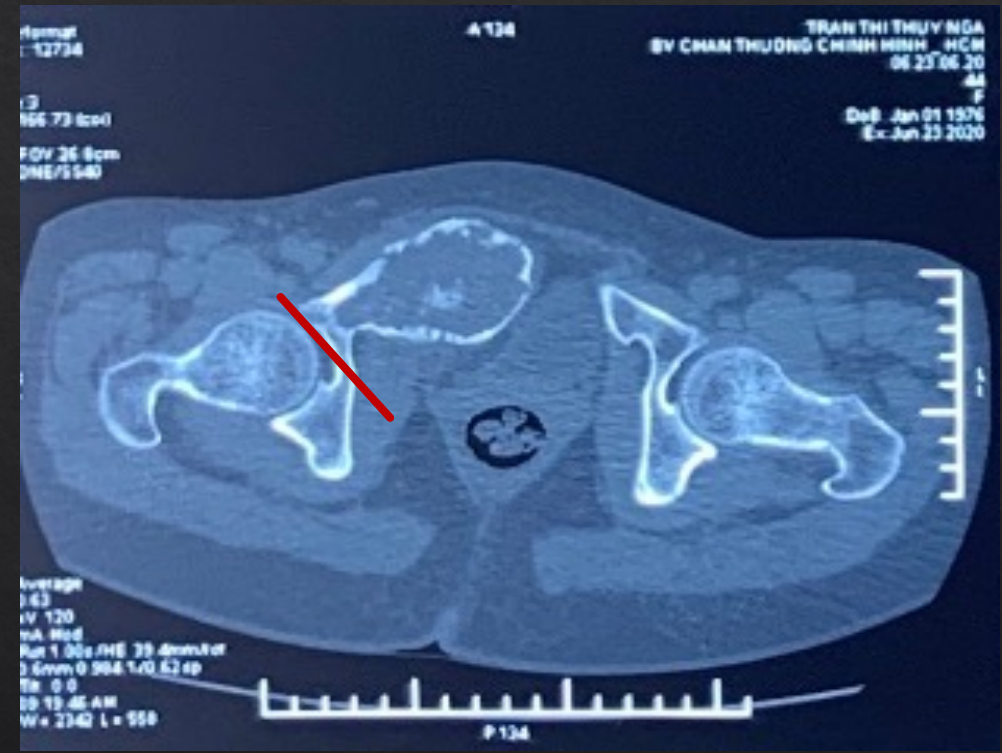
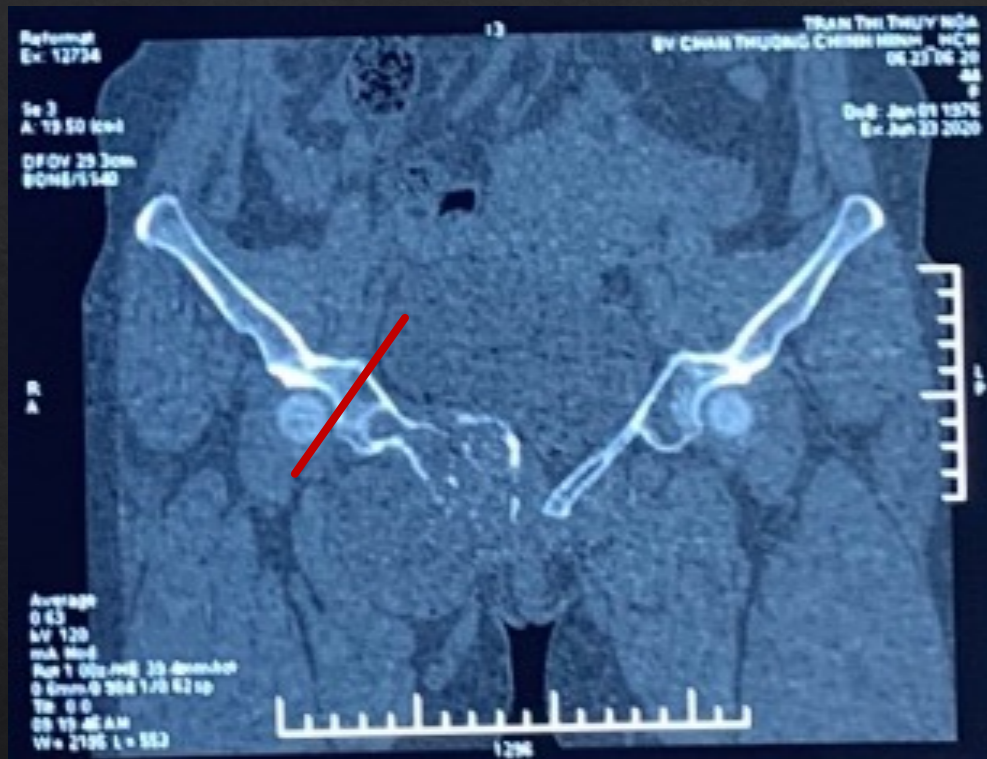Type of pelvic resection (Enneking and Dunham, 1978)

Reconstruction

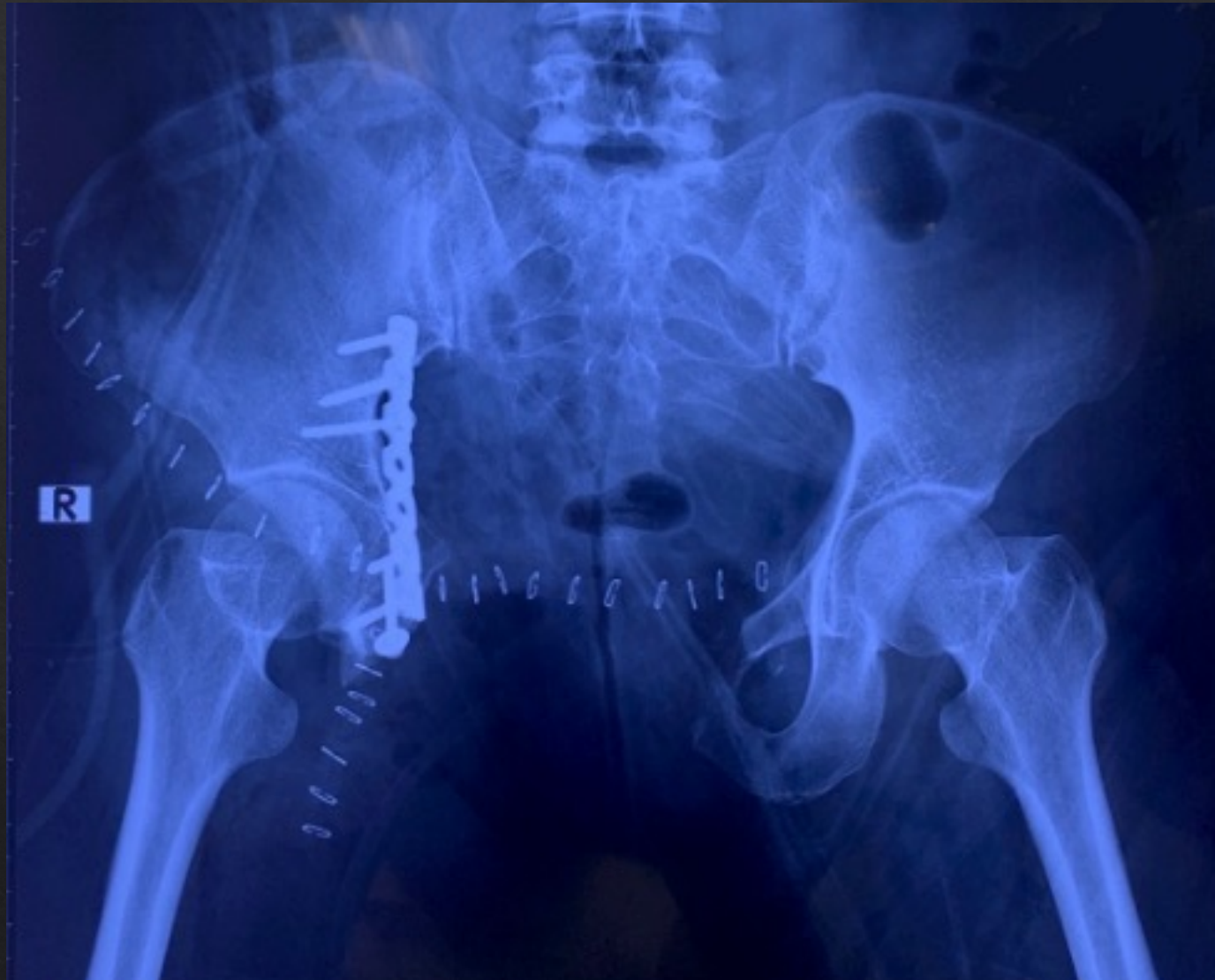

No reconstruction

Reconstruction



Pelvic resection type II + III



Conclusion

- ◆ Pelvic resections: challenging
 - ◆ Complex anatomy
 - ◆ Extent of tumor growth
 - ◆ Reconstruction of the hip joint
- ◆ Limb-salvage pelvic resections can be achieved with advances in imaging and surgical techniques

